

Asymmetry of brain functional activation: fMRI study under language and music stimulation

LI Enzhong 李恩中, WENG Xuchu 翁旭初, HAN Ying 韩 瓔, WU Shaojie 武少杰, ZHUANG Jiancheng 庄建程, CHEN Chuhui 陈楚晖, FENG Ling 冯 玲 and ZHANG Kan 张 侃

Keywords: magnetic resonance imaging • brain • language • music

Objective To determine the asymmetry of the human brain functional activation.

Methods With the help of GE Signa Horizon MRI system, 14 cases of right handed volunteers were examined and the blood oxygenation level dependent method was used. The T1-weighted images were obtained with spin echo pulse sequence and the functional imaging (T2*-weighted) was performed using a single shot echo planar imaging pulse sequence. Data analysis was done with Sun Sparc Workstation and by the method of student t test or correlation analysis.

Results Most of activation areas were in the left hemisphere under language stimulation, while they were in the right side under music stimulation. Besides, a few brain areas in the contralateral cerebral cortex were also activated under both stimulations.

Conclusion The present study supported the hypothesis of the asymmetry of brain functional activation and many brain areas of the cerebral cortex as well as both hemispheres worked in coordination. In addition, it also proved that fMRI is a feasible method in the study of human brain in vivo.

Chin Med J 2000; 113(2): 154-158

It has been reported that the classical model of the dominance of the left hemisphere of human brain is incorrect because it is inaccurate to say that which hemisphere is dominant. The hemispheres are asymmetrical in their function. In this study we tried to find out the activated areas and to confirm the asymmetry of the brain by means of auditory pathway and with the aid of functional magnetic resonance imaging (fMRI) technique.

METHODS

Subjects

Ten men and 4 women were studied. Their age ranged from 23 to 48 years. They were all right-handed and healthy,

i. e. they had psychiatric and neurological disorders and no history of auditory abnormalities.

Assignment

To listen a piece of news or music was used as language or music stimuli. The study pattern was designed as control-task-control-task or vice versa in a single scanning pulse sequence in order to eliminate the noise produced during MR scanning. The assignment was fulfilled by computer and MRI acoustic system.

MR scanning

Signa Horizon 1.5T ultraconductive magnetic resonance imaging system (GE Medical System, Milwaukee, USA) and a quadrature head coil were used. Sagittal, coronal, and axial sections of images were obtained with spin echo T1-weighted imaging pulse sequence, TR 440 ms, TE 11 ms, FOV 24 or 22 cm, matrix 256 × 256, slice thickness 6 or 5 mm, slice space 3 or 2.5 mm. The T1-weighted images upon which the functional data were superimposed were used as the anatomic reference images. The T2-weighted images which were also considered functional data were acquired by blood oxygenation level dependent method with the single shot echo planar imaging pulse sequence, TR 2000 ms, TE 60 ms, matrix 128 × 128, the other parameters were same as the T1-weighted images. Because there was the limit of maximal image numbers of MRI system and the cause of the scanning time length in the experiment, 50 or 100 phases each stage were needed.

Department of MRI, Shougang General Hospital, Beijing, 100041; Institute of Automation, the Chinese Academy of Sciences, Beijing 100080, China (Li EZ)

Laboratory for Higher Brain Function, Institute of Psychology, the Chinese Academy of Sciences, Beijing, 100012, China (Weng XC, Zhuang JC, Feng L and Zhang K)

Department of Neurology, Shougang General Hospital, Beijing, 100041, China (Han Y)

GE Medical System China, Beijing, 100176, China (Wu SJ and Chen CH)

Data analysis

With the help of the Sun Sparc Workstation and associated analysis software, as well as the statistical methods such as student *t* test or cross correlation analysis, the region of interest in the activated areas of the brain was analyzed, and the time-signal intensity curves were obtained (Fig. 1). Besides, with the three dimensional system of the Talairach and Tournoux,¹ the images (Fig. 2) were standardized and the activated areas of the cerebral cortex calculated.

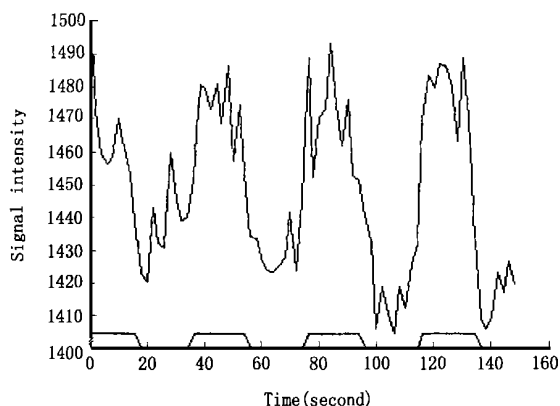


Fig 1. The time signal intensity curve of the activation area in Wernicke's area. The signal of stimulus was in the lower part; the upper part was response curve with big swing.

RESULTS

The activated areas of the cerebral cortex were mainly located in the left hemisphere of the human brain, and also in some areas of the frontal and temporal lobes in the right hemisphere under the condition of language stimulation. Under the stimulation of music, however, the most activated areas were in the right hemisphere and few in the left (Table).

Table The activation areas in the cerebral cortex of the human brain

Cerebral lobes	Language stimulation		Music stimulation			
	Left hemisphere	Right hemisphere	Left hemisphere	Right hemisphere	Left hemisphere	Right hemisphere
Frontal	GFS	9, 10	GFS	9, 10	GFS	9, 10
	GFM	46			GFM	46
	GFI	44, 45			GFI	44, 45
Temporal	GTS	42, 22	GTS	42, 22	GTS	42, 22
	GTM	21	GTM	21	GTM	21
	GTI	20				
	GTP	38			GTP	38
	GU	34			GPH	36
					GSM	40
Parietal	GSM	40				
	GA	39				
Occipital	APE	19			APE	19
					APA	18
Other	TOJ	37			TOJ	37
	GC	24			GC	24, 31, 32

G: gyrus; F: frontal; T: temporal; S: superior; M: middle; I: inferior; PH: parahippocampal; U: uncus; P: pole; SM: supramarginal; A: angular; C: cingulate; APE: peristriate area; APA: parastriate area; TOJ: temporal occipital junction. Numbers: Brodmann's areas.

Language stimulation

Auditory cortex and temporal lobe

In both hemispheres of the brain, the superior temporal gyri including Wernicke's area and the middle temporal gyri were activated. The inferior temporal gyrus (Fig. 3) and uncus in the left hemisphere were also activated.

Classical language areas

The activation of Broca's area, Wernicke's area (Fig. 3), and angular gyrus were observed in the posterior inferior frontal gyrus, posterior superior temporal gyrus and inferior parietal lobule in the left hemisphere.

Other association areas

The superior frontal gyri of both hemispheres were activated mainly in the left and in addition, the middle and inferior frontal gyri, the supramarginal gyrus, the temporo-occipital junction, the cingulate gyrus and the occipital area in the left hemisphere were also activated (Fig. 4).

Music stimulation

Auditory cortex and temporal lobe

By music stimulation, the areas of the superior and middle temporal gyri in both hemispheres were activated outside the Wernicke's area in the left, but predominant in the right (Fig. 5 and 6). With this stimulation, the inferior temporal gyrus whether in the right or in the left hemisphere was not activated. But the parahippocampal gyrus was activated.

Other cerebral areas

The superior frontal gyrus was activated in both hemispheres, and others only in the right hemisphere. Besides, the right supramarginal and cingulate gyri were activated in addition to the temporo-occipital junction and occipital areas.

DISCUSSION

In May 1991, fMRI technique was first used to show the functional activation of the visual cortex by the scientists of Massachusetts General Hospital, USA. This new technique did not cause any radiation injury to the human body and no injection of the tracer was required. Its basic principle is that the deoxyhemoglobin of the region is decreased when the regional area of the cerebral cortex is activated, the regional T2* prolonged, and the signal intensity increased.^{2, 3}

Traditionally, the left hemisphere of human brain is thought to have the ability to control the opposite limbs and such language centers as Broca's and Wernicke's areas. The left cerebral hemisphere or dominant hemisphere, however, was able to control language, script, calculation, and abstract thought. The right controlled music comprehension, spatial cognition, and imaginary thinking.

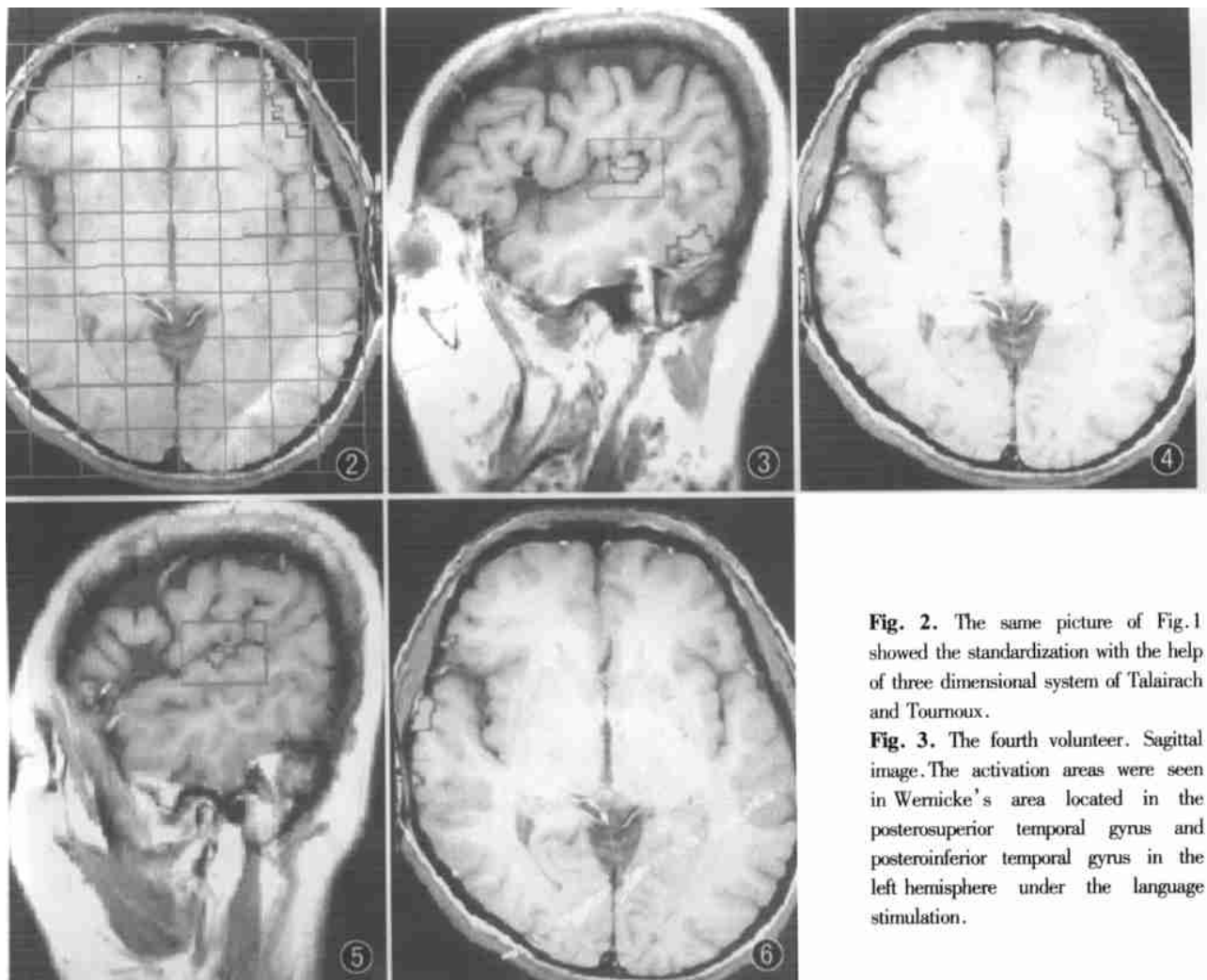


Fig. 2. The same picture of Fig.1 showed the standardization with the help of three dimensional system of Talairach and Tournoux.

Fig. 3. The fourth volunteer. Sagittal image. The activation areas were seen in Wernicke's area located in the posterosuperior temporal gyrus and posteroinferior temporal gyrus in the left hemisphere under the language stimulation.

Fig 4 Axial image. The activated areas in the superior temporal gyrus and superior, middle frontal gyri(Brodmann's areas 9, 46) in the left hemisphere under the language stimulation.

Fig 5. The fifth volunteer. Sagittal image. The activation area was seen only in the superior temporal gyrus in the right hemisphere under the music stimulation, and no activated area was found in the inferior temporal gyrus of both hemispheres.

Fig 6. The same volunteer as Fig. 1. The activated areas in the superior and middle temporal gyri in the right hemisphere under the stimulation of music

Language is an ability of which only human beings possess, and it is defined broadly to include both phonological and semantic functions. Some investigators held that superior and middle temporal gyri play an important role in processing phonetic and auditory information. Both gyri of the two hemispheres are essential to interpretation, self-monitoring of language, and the exchange of information between the two hemispheres, especially in the left one. The inferior temporal gyrus of the left hemisphere is also important in processing the lexical-semantic work.^{4,7} Language generation such as a sentence generation activated middle and inferior frontal gyri in the left hemisphere.⁴ Left anterior temporal cortex outside traditional "language areas" was a portion supporting the linkage between conceptual knowledge and linguistic signs.⁸ Language stimulus thus

could activate the traditional "language areas" such as Broca's area or Wernicke's area and also outside those areas, as was confirmed by this study. Additionally, SPECT, CT and MRI were used to find that the patients with nonfluent aphasia had defects in Broca's area and fluent aphasia in the Wernicke's area, that auditory comprehension defect, repetition deficit and reading abnormality were associated with the defects in the superior and inferior parietal regions, that the damage of the posterior frontal cortex resulted in writing abnormality.⁹ The classical language areas of perisylvian regions and the other areas such as the posteroinferior temporal cortex, parieto-occipital junctions, right prefrontal cortex, superior temporal gyrus and insula were activated¹⁰ in synaesthesia, a phenomenon that hearing a word could result in the

experience of color.

Music stimulus might generate music sense of hearing, feeling and memory, which activated the right hemisphere of the brain. Using PET, Zatorre and coworkers found CBF increased in the right superior temporal and occipital cortices, right frontal, parietal and temporal lobes as well as in the insular cortex, but CBF decreased in the left primary auditory cortex. Clinical investigations found that the patients with right hemisphere infarction in the middle and posterior cerebral artery territories involving the insula complained of lack of musical appreciation. Tests confirmed that they had a dissociated receptive musical deficit in the presence of normal appreciation of environmental sounds and speech,¹² known as amusia. Horikoshi¹³ and his associates treated a patient with an intracerebral hematoma caused by an arteriovenous malformation of the left occipital parasplenic region. Postoperatively they found that the patient was normal in singing, playing of melodies and dictating music notes, but not in reading music and other symbolic figures. These results suggested that her figures underwent a preliminary verbal decoding in the left hemisphere.

In this study, language and music were used as the stimuli. The areas in the left hemisphere of the human brain were subjected to the stimulation of the language and those in the right to the stimulation of music (Table). The results confirmed the theory that both hemispheres have different functions.

In our study, the superior frontal and superior (non Wernicke's area), middle temporal gyri in both hemispheres were activated by either of the two stimulations. But, the middle and inferior frontal gyri (including Broca's area), superior (Wernicke's area) and inferior temporal gyri, anterior cingulate gyrus, angular gyrus and uncus in the left hemisphere only subjected to the language stimulation. The activation areas were seen only in the middle and inferior frontal gyri, supramarginal gyrus and parahippocampal gyrus in the right hemisphere under the stimulation of music in contrast to the inferior temporal gyrus of both sides. These results supported not only the hypothesis about the function of language expression in Broca's area, auditory language centrum in Wernicke's area, visual language centrum in the angular gyrus and supramarginal gyrus spatial cognition and music comprehension, but also the points of view about the function of sound or auditory information processing in both superior and middle temporal gyri, lexico-semantic processing of language in the left inferior temporal gyrus, and language generation in the left middle and inferior frontal gyri. In addition, only anterior cingulate gyrus was activated by language stimulation (Brodmann's area 24),

and some areas of cingulate gyrus were activated by music stimulation (Brodmann's area 24, 31, 32). We suggested that Brodmann's area 24 might be related to the work memory and Brodmann's areas 31, 32 to the attention or emotion. The superior frontal gyri of both hemispheres were activated by both language and music stimulations. Possibly, the gyri might be the center of working memory and the executive control unit.¹⁴ The functions of the activated areas in parahippocampal gyrus and uncus were not clear, they might be related to the emotion or temporary memory.

In general, most of the areas stimulated by language were in the left hemisphere of the brain and the activation areas of the cortex were not only limited in the classical "language areas", but also in the other areas of the cerebral cortex.¹⁵ Besides, some areas were also activated in the right hemisphere. Music stimulation resulted in activation of the areas of the right hemisphere and still numerous areas of the cerebral cortex participated in the functional activation just like language stimulation. These indicated that whether language or music stimulation, many different areas in one hemisphere or in some areas of both hemispheres work in coordination, even though the two hemispheres have different functions.

Acknowledgement: This work was granted by the Ministry of Labor and Social Security. We thank Drs. Wang Nan and Ta Mingyi, director and deputy director of our hospital, Mr. Hu Hao and other colleagues for their support to this experiment. We specially thank Zhao Feng and Liu Jingwei for their assistance in grant application.

REFERENCES

1. Talairach J and Tournoux P. Co-planar stereotaxic atlas of the human brain. New York: Thieme, 1988; F 120.
2. Kwong KK. Functional magnetic resonance imaging with echo planar imaging. *Magn Reson Quart* 1995; 11: F 20.
3. Li EZ, Ma L, Weng XC. The preliminary study of the functional MR imaging. *Chin J Med Imaging* 1996; 4: 209-211.
4. Muller RA, Rothenmel RD, Behen ME, et al. Receptive and expressive language activations for sentences: a PET study. *Neuroreport* 1997; 8(17): 3767-3770.
5. Karbe H, Wurker M, Herholz K, et al. Planum temporale and Brodmann's area 22 magnetic resonance imaging and high resolution positron emission tomography demonstrate functional left-right asymmetry. *Arch Neurol* 1995; 52: 869-874.
6. Pearlson GD. Superior temporal gyrus and planumtemporale in schizophrenia: a selective review. *Prog Neuropsychopharmacol Biol Psychiatry* 1997; 21: 1203-1229.
7. Binder JR, Rao SM, Hammeke TA, et al. Functional magnetic resonance imaging of human auditory cortex. *Ann Neurol* 1994; 35(6): 662-672.
8. Anderson SW, Damashio H, Damashio AR, et al. Acquisition of signs from American sign language in hearing individuals following left hemisphere damage and aphasia. *Neuropsychologia* 1992; 30: 329-340.

9. Janicek MJ, Schwartz RB, Carvalho PA, et al. Tc 99m HMPAO brain perfusion SPECT in acute aphasia: correlation with clinical and structural findings. *Clin Nucl Med* 1993; 18(12): 1032-1038
10. Paulesu E, Harrison J, Baron Cohen S, et al. The physiology of the coloured hearing: a PET activation study of colour word synaesthesia. *Brain* 1995; 118(pt3): 661-676.
11. Zatorre RJ, Evans AC, Meyer E. Neural mechanisms underlying melodic perception and memory for pitch. *J Neurosci* 1994; 14: 1908-1919.
12. Griffinths TD, Rees A, Witton C, et al. Spatial and temporal auditory processing deficits following right hemisphere infarction: a

psychophysical study. *Brain* 1997; 120(pt5): 785-794.

13. Horikoshi T, Asari Y, Watanabe A, et al. Music alexia in a patient with mild pure alexia: disturbed visual perception of nonverbal meaningful figures. *Cortex* 1997; 33: 187-194.
14. Baddley A, Della Sala S. Working memory and executive control. *Phil Trans R Soc Lond B* 1996; 351: 1397-1401.
15. Binder JR, Frost JA, Hammeke TA, et al. Human brain language areas identified by functional magnetic resonance imaging. *J Neurosci* 1997; 17: 353-362.

(Received July 11, 1999)

本文编辑: 钱寿初

Detection of human parvovirus B19 DNA in children with aplastic anemia and idiopathic thrombocytopenic purpura

QIAN Xinhong 钱新宏, ZHENG Yuejie 郑跃杰, JIAO Xiyong 焦西英 and ZHANG Guocheng 张国成

Objective To investigate the role of human parvovirus B19 (HPV B19) infection in the occurrence of aplastic anemia (AA) and idiopathic thrombocytopenic purpura (ITP).

Methods From April 1995 to October 1996 sixty-four patients (40 cases of AA and 24 cases of ITP) at Xijing Hospital were enrolled in this study. Among them, 38 were boys, 26 girls, with age ranging from 1 to 12 years. Control group consisted of 30 healthy children during the same period. From each of them, 2 ml of peripheral blood was taken. For the nested polymerase chain reaction (PCR) study, 50 μ l of serum was added to a 100 μ l of solution containing 10 μ g of proteinase K, which was incubated at 65 $^{\circ}$ C for 1 hour and then at 95 $^{\circ}$ C for 10 minutes to inactivate the proteinase K. The formed precipitate was then centrifuged at 14 000 r/m for 15 minutes, and 5 μ l of the supernatant was used as the PCR template. The nested PCR amplification was done as follows: 5 μ l of each template

was added to reach 50 μ l of PCR reaction volume, containing 31 μ l of bidistilled water, 5 μ l of buffer, 200 μ mol/L of each dNTP, 1 unit Taq DNA polymerase and 300 ng of each primer. Thirty-five cycles of both first and second round PCR amplification were performed under the following conditions: 95 $^{\circ}$ C for 1 minute, 55 $^{\circ}$ C for 1.5 minutes, and 72 $^{\circ}$ C for 1 minute. The amplified fragments were 1112 bp and 104 bp respectively. The second PCR product was electrophoresed on 2% agarose gel, and visualized in UV light. The band position was compared with that of HPV B19-DNA positive control.

Results The samples of sera obtained from 40 AA patients, 24 ITP patients and 30 healthy children were analyzed for the HPV B19-DNA. The positive rates of HPV B19-DNA were 25.0 (10/40) and 29.2 (7/24) in AA and ITP patients respectively, which were significantly higher than those in the control group (3.3%, $P < 0.05$).

Conclusion HPV B19 infection is closely related to the onset of AA, as well as ITP, and may be an important cause of childhood AA and ITP.

(Received January 26, 1999)

本文编辑: 杨振铎

Department of Pediatrics, Xijing Hospital, the Fourth Military Medical University, Xi'an 710032, China (Qian XH, Zheng YJ, Jiao XY and Zhang GC)

This study was supported by the Starting Fund for Returned Scholars of PLA (No. 947008)