

# Decreased gyrification in major depressive disorder

Yuanchao Zhang<sup>a,b</sup>, Chunshui Yu<sup>c</sup>, Yuan Zhou<sup>b,d</sup>, Kuncheng Li<sup>c</sup>,  
Chong Li<sup>a,b</sup> and Tianzi Jiang<sup>b</sup>

**Structural and functional abnormalities have been extensively reported in major depressive disorder, but possible changes in cortical folding have not yet been explored in this disorder. This study investigated this issue in major depressive disorder using the local gyrification index. High-resolution magnetic resonance imaging was performed in 18 patients with first-episode major depressive disorder and 18 age-matched and sex-matched healthy individuals. The local gyrification index was applied to detect brain areas with abnormal cortical folding in major depressive disorder. Compared with healthy participants, patients with major depressive disorder showed significantly decreased local gyrification index in the bilateral mid-posterior cingulate, insula, and orbital frontal cortices, the left anterior cingulate cortex, and the right temporal operculum. *NeuroReport* 20:378–380 © 2009 Wolters Kluwer Health | Lippincott Williams & Wilkins.**

*NeuroReport* 2009, 20:378–380

**Keywords:** complexity, connectivity, cortical folding, local gyrification index, magnetic resonance imaging, major depressive disorder

<sup>a</sup>Department of Mathematics, Zhejiang University, Hangzhou, <sup>b</sup>National Laboratory of Pattern Recognition, Institute of Automation, Chinese Academy of Sciences, <sup>c</sup>Department of Radiology, Xuanwu Hospital of Capital Medical University and <sup>d</sup>Center for Social and Economic Behavior, Institute of Psychology, Chinese Academy of Sciences, Beijing, PR China

Correspondence to Professor Tianzi Jiang, PhD, National Laboratory of Pattern Recognition, Institute of Automation, Chinese Academy of Sciences, Beijing 100190, PR China

Tel: +86 10 8261 4469; fax: +86 10 62551993;  
e-mail: jiangtz@nlpr.ia.ac.cn

Yuanchao Zhang, Chunshui Yu, and Yuan Zhou contributed equally to this study

Received 28 November 2008 accepted 30 November 2008

## Introduction

Major depressive disorder (MDD) is a common psychiatric illness, which is characterized by persistent and overwhelming feelings of sadness, guilt, and worthlessness. It is believed that depression is related to the disturbance in connectivities between multiple brain regions [1]. This opinion is supported by abnormalities in both cortico–cortical connectivity revealed by disrupted white matter integrity [2] and intracortical organization revealed by glial cell pathology in MDD [3–5]. Cortical folding, which can be investigated by gyrification measures, is thought to reflect not only cortico–cortical connectivity [6] but also optimal intracortical organization, with the most axonal connections in the least possible volume [7]. Therefore, investigating the pattern of cortical folding in MDD patients may contribute in understanding the pathogenesis of the disorder.

The gyrification index (GI) proposed by Zilles *et al.* [8] is a quantitative measure of gyrification, but this method is rather dependent and cannot localize the exact regions with abnormal cortical folding. The local gyrification index (LGI), a three-dimensional extension of GI, is a newly developed, automated method for locating regionally specific changes in gyrification, and has been successfully used to assess gyrification of the 22q11 Deletion syndrome [9]. In this study, we use this measure to explore gyrification abnormalities in MDD.

## Materials and methods

### Participants

Eighteen medication-naïve patients with first major depressive episode (four men and 14 women) were recruited from the outpatient clinic at Xuanwu Hospital and met the following criteria: (i) *Diagnostic and Statistical Manual of Mental Disorders* 4th edition criteria for a major depressive episode, single episode, currently depressed, according to the structured clinical interview for *Diagnostic and Statistical Manual of mental disorders* fourth edition; (ii) never exposed to any psychotropic medication before the assessment began; (iii) age 18–60 years; (iv) no history of substance abuse or dependence, no family history of major psychiatric or neurological illness in first-degree relatives, not currently taking any prescription or centrally acting medications, no serious medical or neurological illness; and (v) satisfying the criteria to undergo a magnetic resonance imaging (MRI) scan based on a MRI screening questionnaire. The patients were excluded for any axis I disorder (other than MDD) that preceded the onset of MDD. Additional exclusion criteria were as follows: acutely suicidal or homicidal or requiring inpatient treatment, history of trauma resulting in loss of consciousness, current pregnancy, or breastfeeding. At the time of scanning, the depressive symptoms of the patients were rated using the 17-item Hamilton Depression Rating Scale ( $17.8 \pm 3.6$ ). Eighteen demographically matched healthy participants (four men and 14 women) were recruited by

advertisements and met the same inclusion criteria (iii–v) and the exclusion criteria as the patients. All participants took part in this study after signing an informed consent form approved by the Medical Research Ethics Committee of Xuanwu Hospital. The mean duration of current depressive episode of MDD patients was  $6.7 \pm 3.9$  months. No patients were on antidepressant medications at the time of scanning. The two groups were statistically comparable in age ( $39.8 \pm 9.3$  years for MDD;  $39.0 \pm 10.7$  years for healthy participants;  $P=0.8173$ ) and sex composition ( $P=1$ ).

### MRI data acquisition

Three-dimensional structural MRI scans were obtained on a 3.0 Tesla magnetic resonance scanner (Trio system; Siemens Magnetom scanner, Erlangen, Germany) with magnetization prepared rapid acquisition gradient echo (MP-RAGE). Detailed scan parameters were as follows: repetition time = 2000 ms, echo time = 2.6 ms, slice thickness = 1 mm, no gaps, flip angle =  $9^\circ$ , matrix =  $256 \times 224$ , field of view =  $256 \times 224 \text{ mm}^2$ ,  $1 \times 1 \text{ mm}^2$  in-plane resolution.

### Image data analysis

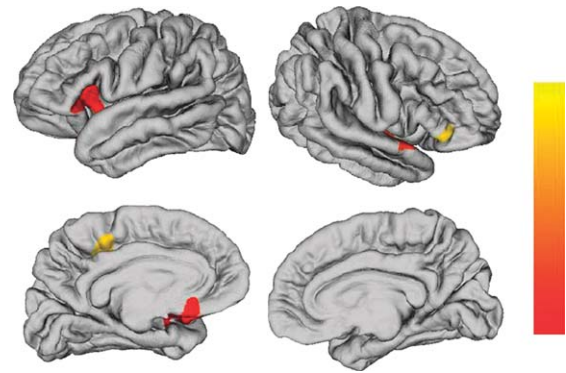
Each scan was processed using FreeSurfer [10,11] (<http://surfer.nmr.mgh.harvard.edu/>) to obtain the complexity measure (IGI). In brief, a cortical map of IGIs can be obtained in four steps [9]. First, the pial cortical surface is reconstructed in three-dimensional space. Second, an outer surface can be obtained from the outer hull that tightly warps the pial surface. Third, the IGI is computed for each of the vertices of the outer surface. Fourth, a cortical map of IGIs is obtained by propagating the IGI values from the outer surface mesh to the pial surface mesh.

To compare the IGIs point by point, the establishment of point correspondence across participants in a standard surface-based coordinate system was required. Surface-based registration [12] was used to build an average template and all of the individual reconstructed cortical surfaces were aligned to the template. A heat kernel of 10 mm width was used to smooth the IGI maps. Before the statistical analysis, a linear regression was performed to remove the effects of age and sex. The residuals of the regression were used for statistical analysis.

### Statistical analyses

Statistical analysis was performed at every point across all participants in Montreal Neurological Institute space. Two-sample *t*-tests were used to test statistically significant differences in IGIs at homologous vertices. The threshold  $P=0.001$  was used to define clusters, and only clusters with a minimum of 50 points were reported. Then corrected cluster-wise *P* value was obtained using random field theory [13]. The level of significance for clusters was set at *P* value of less than 0.05 after multiple comparison correction.

Fig. 1



Brain regions of significantly decreased local gyrification index in patients with major depressive disorder compared with well-matched healthy participants after a correction for multiple comparisons ( $P < 0.05$ , the cluster-based random field theory correction). The color bar indicates the cluster-wise *P* value after the correction for multiple comparisons.

### Results

Only decreased IGI was found in MDD patients compared with healthy participants. We found nine clusters of difference with thresholds of  $P=0.001$  (uncorrected) and cluster size  $\geq 50$  points. These clusters included the bilateral mid-posterior cingulate, insula, and orbital frontal cortices, the left anterior cingulate cortex, and the right temporal operculum. After performing multiple comparison correction using random field theory, we identified five significant clusters, which included the left insular/frontal operculum (cluster size=2184 points, corrected *P* value=0.0039), the left medial orbital frontal cortex (cluster size=1907 points, corrected *P* value=0.0021), the left mid-posterior cingulate cortex (cluster size=1041 points, corrected *P* value=0.0428), the right insula/temporal operculum (cluster size=1471 points, corrected *P* value=0.0113), and the right inferior frontal gyrus (cluster size=303 points, corrected *P* value=0.0444) (Fig. 1).

### Discussion

In this study, we used a surface-based approach to quantify the local cortical gyrification in well-matched samples of MDD patients versus healthy participants. We revealed decreased gyrification in MDD patients compared with healthy participants in certain mood-related brain areas.

There are several possible explanations for the decreased cortical gyrification in the regions we detected. A mechanical model of brain convolutional development has been used to explain abnormalities in cortical folding during human brain development [14]. This model proposes that differential growth rates of cortical layers directly affect the degree of cortical convolutions. In fact, several previous

studies have found decreased glial density, neuronal density, and neuronal size in several mood-related regions such as the anterior cingulate cortex [4] and the orbitofrontal cortex [3,5] in MDD. Therefore, the decreased gyrification in the mood-related regions might be caused by disorganization of the cortical architectures in these regions. Another tension-based model of cortical morphogenesis proposes that tension along the axons in white matter is the primary driving force for cortical folding [6]. In MDD, previous diffusion tensor imaging studies have revealed that depressive patients had a significantly lower fractional anisotropy in the prefrontal white matter [2]. In addition, in previous diffusion tensor imaging studies, white matter abnormalities of the anterior cingulate cortex, the prefrontal lobe, the insula, and the posterior cingulate regions have been reported in patients with geriatric depression [15–17]. According to the tension-based theory of cortical morphogenesis, the decreased gyrification might be because of the abnormal connectivity caused by white matter abnormalities in these regions.

The hypothesis that MDD is of neurodevelopmental origin has been proposed recently. In the neurodevelopmental perspective, MDD is considered to result from a combination of genetic and harmful environmental factors during the developmental process [18]. Studies have shown that both environmental and genetic factors may have an effect on the patterns of cortical folding. For example, sheep fetuses, which were exposed to short periods of mid-gestation hypoxia, showed significantly reduced surface folding index compared with controls [19]. In addition, a study on the human brain has shown that mutations in GPR56, which encodes an orphan G protein-coupled receptor, can cause a cortical malformation called bilateral frontoparietal polymicrogyria [20]. In the perspective of neuroplasticity, environmental factors have been shown to influence the morphology of brain circuits during adulthood. For example, in a study about the impact of chronic stress on the brain of rat [21], researchers found that chronic stress can alter dendritic morphology in medial prefrontal cortex, which is an important part of limbic-thalamic-cortical circuits. In addition, another study reported that chronic stress can inhibit cell proliferation in medial prefrontal cortex of adult rat, and this suppressive effect of stress can be reversed by antidepressant treatment [22]. Therefore, it is possible that abnormalities in genetic and/or environmental factors during the developmental process and adulthood may contribute to the decreased gyrification in mood-related regions that we observed.

## Conclusion

In conclusion, we found decreased gyrification in several mood-related regions in patients with MDD compared with healthy participants. To our knowledge, this is the first study to explore the cortical folding pattern in MDD. Further studies are needed to clarify the exact mechanism of the abnormal cortical folding in MDD.

## Acknowledgements

The authors thank Marie Schaer, Lei Lin, Kun Wang for their useful suggestions and Jiefeng Jiang, Yongfu Hao, Professor Keith J. Worsley for their help on the artwork. The authors also thank Dr Edmund F. and Dr Rhoda E. Perozzi for checking the English. This work was supported by the Natural Science Foundation of China, grant no. 30425004, 30670601, 30870694, and 30730035, and the National Key Basic Research and Development Program (973), grant no. 2007CB512300.

## References

- 1 Mayberg HS. Modulating dysfunctional limbic-cortical circuits in depression: towards development of brain-based algorithms for diagnosis and optimised treatment. *Br Med Bull* 2003; **65**:193–207.
- 2 Li L, Ma N, Li Z, Tan L, Liu J, Gong G, et al. Prefrontal white matter abnormalities in young adult with major depressive disorder: a diffusion tensor imaging study. *Brain Res* 2007; **1168**:124–128.
- 3 Cotter D, Mackay D, Chana G, Beasley C, Landau S, Everall IP. Reduced neuronal size and glial cell density in area 9 of the dorsolateral prefrontal cortex in subjects with major depressive disorder. *Cereb Cortex* 2002; **12**:386–394.
- 4 Cotter D, Mackay D, Landau S, Kerwin R, Everall I. Reduced glial cell density and neuronal size in the anterior cingulate cortex in major depressive disorder. *Arch Gen Psychiatry* 2001; **58**:545–553.
- 5 Rajkowska G, Miguel-Hidalgo JJ, Wei J, Dille G, Pittman SD, Meltzer HY, et al. Morphometric evidence for neuronal and glial prefrontal cell pathology in major depression. *Biol Psychiatry* 1999; **45**:1085–1098.
- 6 Van Essen DC. A tension-based theory of morphogenesis and compact wiring in the central nervous system. *Nature* 1997; **385**:313–318.
- 7 Klyachko VA, Stevens CF. Connectivity optimization and the positioning of cortical areas. *Proc Natl Acad Sci U S A* 2003; **100**:7937–7941.
- 8 Zilles K, Armstrong E, Schleicher A, Kretschmann HJ. The human pattern of gyrification in the cerebral cortex. *Anat Embryol (Berl)* 1988; **179**:173–179.
- 9 Schaer M, Cuadra MB, Tamarit L, Lazeyras F, Eliez S, Thiran JP. A surface-based approach to quantify local cortical gyrification. *IEEE Trans Med Imaging* 2008; **27**:161–170.
- 10 Dale AM, Fischl B, Sereno MI. Cortical surface-based analysis. I. Segmentation and surface reconstruction. *NeuroImage* 1999; **9**:179–194.
- 11 Fischl B, Sereno MI, Dale AM. Cortical surface-based analysis. II: Inflation, flattening, and a surface-based coordinate system. *NeuroImage* 1999; **9**:195–207.
- 12 Fischl B, Sereno MI, Tootell RB, Dale AM. High-resolution intersubject averaging and a coordinate system for the cortical surface. *Hum Brain Mapp* 1999; **8**:272–284.
- 13 Hayasaka S, Phan KL, Liberzon I, Worsley KJ, Nichols TE. Nonstationary cluster-size inference with random field and permutation methods. *NeuroImage* 2004; **22**:676–687.
- 14 Caviness VS Jr. Mechanical model of brain convolutional development. *Science (New York, NY)* 1975; **189**:18–21.
- 15 Alexopoulos GS, Murphy CF, Gunning-Dixon FM, Latoussakis V, Kanellopoulos D, Klimstra S, et al. Microstructural white matter abnormalities and remission of geriatric depression. *Am J Psychiatry* 2008; **165**:238–244.
- 16 Taylor WD, MacFall JR, Payne ME, McQuoid DR, Provenzale JM, Steffens DC, et al. Late-life depression and microstructural abnormalities in dorsolateral prefrontal cortex white matter. *Am J Psychiatry* 2004; **161**:1293–1296.
- 17 Yuan Y, Zhang Z, Bai F, Yu H, Shi Y, Qian Y, et al. White matter integrity of the whole brain is disrupted in first-episode remitted geriatric depression. *NeuroReport* 2007; **18**:1845–1849.
- 18 Ansorge MS, Hen R, Gingrich JA. Neurodevelopmental origins of depressive disorders. *Curr Opin Pharmacol* 2007; **7**:8–17.
- 19 Rees S, Stringer M, Just Y, Hooper SB, Harding R. The vulnerability of the fetal sheep brain to hypoxemia at mid-gestation. *Brain Res* 1997; **103**:103–118.
- 20 Piao X, Hill RS, Bodell A, Chang BS, Basel-Vanagaitte L, Straussberg R, et al. G protein-coupled receptor-dependent development of human frontal cortex. *Science (New York, NY)* 2004; **303**:2033–2036.
- 21 Czeh B, Perez-Cruz C, Fuchs E, Flugge G. Chronic stress-induced cellular changes in the medial prefrontal cortex and their potential clinical implications: does hemisphere location matter? *Behav Brain Res* 2008; **190**:1–13.
- 22 Czeh B, Muller-Keuker JI, Rygula R, Abumaria N, Hiemke C, Domenici E, et al. Chronic social stress inhibits cell proliferation in the adult medial prefrontal cortex: hemispheric asymmetry and reversal by fluoxetine treatment. *Neuropsychopharmacology* 2007; **32**:1490–1503.