

# Involvement of secondary motor areas in externally-triggered single-finger movements of dominant and non-dominant hands

GU Yun<sup>1,2\*</sup>, ZANG Yufeng<sup>1</sup>, WENG Xuchu<sup>1</sup>,  
JIA Fucang<sup>1</sup>, LI Enzhong<sup>3</sup> & WANG Jiangjun<sup>2</sup>

1. Laboratory for Higher Brain Function, Institute of Psychology, Chinese Academy of Sciences, Beijing 100101, China;
2. Department of Biological Science and Technology, Nanjing University, Nanjing 210093, China;
3. Department of MRI, Shougang General Hospital, Beijing 100041, China

Correspondence should be addressed to Weng Xuchu (e-mail: wengxc@psych.ac.cn)

\* Present address: The Second Clinical Medical College, Nanjing University of Traditional Chinese Medicine, Nanjing 210029, China

**Abstract** Whether the secondary motor areas are involved in simple voluntary movements remains controversial. Differences in the neural substrates of movements with the dominant and the non-dominant hands have not been well documented. In the present study, functional magnetic resonance imaging (fMRI) was used to investigate the hemodynamic response in the primary motor cortex (M1), supplementary motor area (SMA) and premotor cortex (PMC) in six healthy right-handed subjects while performing a visually-guided finger-tapping task with their dominant or non-dominant hands. Significant activation was observed in M1, SMA and PMC during this externally triggered simple voluntary movement task. While dominant hand movements only activated contralateral motor areas, non-dominant hand movements also activated ipsilateral SMA and PMC. The results provide strong evidence for the involvement of the secondary motor areas in simple voluntary movements, and also suggest that movements of the dominant hand primarily engage the contralateral secondary motor areas, whereas movements of the non-dominant hand engage bilateral secondary motor areas.

**Keywords:** functional magnetic resonance imaging (fMRI), primary motor cortex (M1), secondary motor areas, supplementary motor area (SMA), premotor cortex (PMC), simple voluntary movement, dominant hand.

DOI: 10.1360/02wc0112

A number of studies have demonstrated that the primary motor cortex (M1) and the secondary motor areas, including premotor cortex (PMC) and supplementary motor area (SMA), are involved in voluntary movements. The specific role of these secondary motor areas, however, remains controversial<sup>[1-3]</sup>. For example, there are two

opposite viewpoints on whether the secondary motor areas are involved in simple voluntary movements. One classical viewpoint is that only M1, presumably lower in the hierarchy of motor function, but not the secondary motor areas, presumably higher motor control centers, is engaged in simple voluntary movements<sup>[4,5]</sup>. In contrast, others believe that the secondary motor areas are involved in both simple and complex movements<sup>[6-8]</sup>. Colebatch et al.<sup>[6]</sup> found that the secondary motor areas were indeed activated during simple movements but only at relatively high movement rate (1.5 Hz). As this activation could be attributed to higher demands during movements at higher rate, further studies are needed to clarify whether the secondary motor areas are indeed involved in simple movements.

It should be noted that the above studies mainly investigated activation in the secondary motor areas for the dominant hand movements but not for the non-dominant hand movements. In recent years, although several studies investigated neural correlates of voluntary movements in right- and left-handed subjects<sup>[9-12]</sup>, no study, to our knowledge, was designed to directly compare brain activation resulting from the dominant and the non-dominant hand movements. Volkmann et al.<sup>[10]</sup> and Dassonville et al.<sup>[12]</sup> both showed that the activation volume in M1 during the dominant hand movements was larger than that during the non-dominant hand movements, but failed to observe any difference in activation volume in the secondary motor areas. More recently, Solodkin et al.<sup>[11]</sup> reported activation in the contralateral primary motor cortex and secondary motor areas in the right-handed subjects when performing simple movements, whereas in left-handed subjects, bilateral activation was found in all motor areas. Thus, while these studies highlighted the functional differences of motor areas between right- and left-handed subjects, they did not provide information about differences in activation pattern of motor areas during the dominant and the non-dominant hand movements. Furthermore, in these studies, the dominant and the non-dominant hand movement tasks were conducted in different scan sessions, which introduces difficulty in comparing the two tasks and may reduce the statistical power of their analysis.

In the present study, we used functional magnetic resonance imaging (fMRI) technique<sup>[13,14]</sup> to test whether the secondary motor areas are involved in simple movements. We also planned to directly compare the engagement of the primary motor cortex and secondary motor areas in dominant and non-dominant hand movements. A single finger-tapping task at low rate of 0.5 Hz was used to control the complexity of the movements and blocks of the dominant and the non-dominant hand movements were randomly distributed in the same scanning session to make the tasks more comparable. Furthermore, in order to characterize the activation pattern associated with movements, the time course of the

activation in each area was also examined.

## 1 Materials and methods

( ) Subjects. Six healthy volunteers (3 males), ranging in the age of 18—20 years, served as subjects. All were right-handed as determined by a Chinese version of a standardized inventory<sup>[15]</sup>. None had any history of psychiatric and neurological problems. All participants took no medicine during the experiment.

( ) Behavioral task and experimental design

(1) Behavioral task. The subjects performed finger tapping with their left or right index fingers guided by a visual cue, presented on a screen through an LCD projector. The cue could be seen through a small mirror mounted on the head coil.

(2) Experimental design. Block design was used<sup>[16]</sup> (Fig. 1). Each block, having 10 trials of movements, lasted 20 s. In each block, the same finger task was performed repeatedly at the rate of 0.5 Hz. The blocks of right and left hand motor tasks were repeated six times each and the sequence of the block type was randomized. A control period of 20 s was inserted between neighboring motor task blocks, in which the subjects were instructed to keep their fingers stationary. The scanning session lasted 512 s, including the control periods of 24 s at the beginning and of 28 s at the end of the scanning.

( ) MRI equipments and scanning parameters. A 1.5T GE Signa horizon magnetic resonance imaging system was used. The scanning procedures were similar to those reported in our previous studies<sup>[16,17]</sup>.

(1) Scanning for positioning images. Eleven sagittal slices were acquired with a T<sub>1</sub>-weighted spin echo sequence with repetition time (TR) = 440 ms, echo time (TE) = 11 ms, slice thickness = 6 mm, skip = 3 mm, field of view (FOV) = 240 mm × 240 mm, matrix = 256 × 192.

The medial image was used to determine appropriate positions for acquisition of anatomic images.

(2) Scanning for anatomic images. In reference to the positioning images, two axial slices were selected covering M1 and SMA with a T<sub>1</sub>-weighted spin echo sequence (TR = 440 ms, TE = 11 ms, slice thickness = 5 mm, skip = 2.5 mm, FOV = 220 mm × 220 mm, matrix = 256 × 256).

(3) Scanning for functional images. Two slices of T<sub>2</sub>-weighted images were collected using a gradient-echo echo planar imaging sequence in the same position as anatomic images (TR = 2000 ms, TE = 60 ms, flip angle = 90°, FOV = 220 mm × 220 mm, matrix = 64 × 64). A total of 256 functional images were obtained for each slice, for a total length of 512 s.

(4) Scanning for 3-dimensional whole-brain anatomical images. 124 contiguous T<sub>1</sub>-weighted sagittal images, covering the whole brain volume, were collected with a spoiled gradient-recalled at steady-state (SPGR) sequence (TR = 11.1 ms, TE = 4.2 ms, flip angle = 45°, NEX = 2, thickness = 1.5 mm, FOV = 220 mm × 220 mm, matrix = 256 × 256).

( ) Data analysis. The AFNI (analysis of functional neuro-images from Biophysics Research Institute at Medical College of Wisconsin) package<sup>[18]</sup> was used for data analysis and image display.

(1) Preprocessing. Functional images were co-registered to correct head-motion artifacts and possible drift of the baseline was also detrended. These images were then aligned with the 3-dimensional whole-brain anatomic images, normalized according to the standard coordinates defined by Talairach and Tournoux atlas, and re-sampled with a voxel size of 3 mm × 3 mm × 3 mm. Finally, these functional images were spatially smoothed with an isotropic Gaussian kernel (full width at half-maximum, FWHM = 5 mm) to enhance the signal-to-noise ratio.

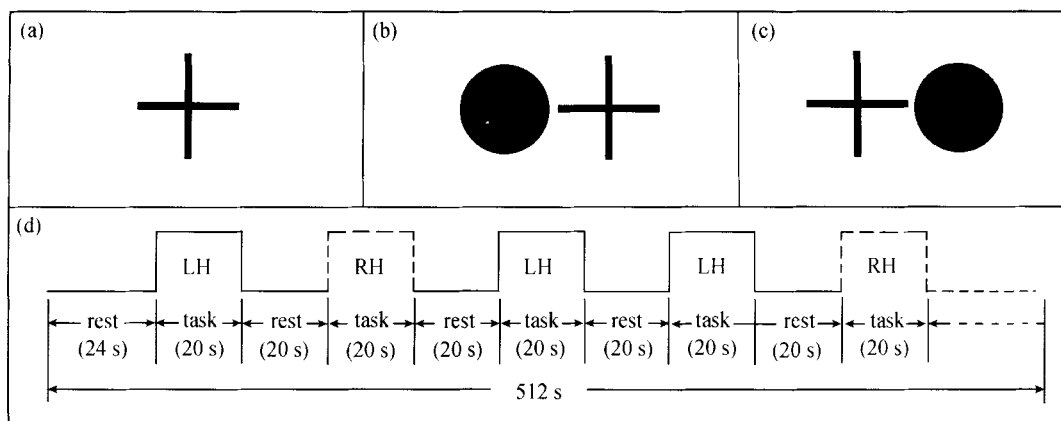


Fig. 1. The visual cues of the task and the experimental procedure. (a) The control cue (fixation); (b) and (c) the task cue, a filled blue circle, for movements of left and right hand, respectively. Subjects were instructed to tap their left index finger if the cue was presented on the left side of the fixation point, and tap their right index finger if the cue appeared on the right; (d) the arrangement of the task. Blocks of left and right hand motor tasks (LH and RH) were randomly arranged in the same scanning session.

(2) Generating statistical parametric maps. The  $F$  value associated with the impulse response function, which is a statistical evaluation of the fitness between the estimated model and the observed data, and its corresponding  $P$  value in each voxel were calculated with the deconvolution analysis (essentially a multiple linear regression analysis). Only the voxels whose  $P$  values equal to or above the statistical threshold were defined as active (see Fig. 2). These "active" voxels were superimposed on the normalized 3-dimensional whole-brain anatomic images to produce statistical parametric maps with pseudo-colors indicating the  $P$  values. To minimize the variability among subjects, the statistical parametric maps of all studied subjects were averaged. To further increase the reliability of the results, only clusters of conjunctively activated voxels with volume more than  $300 \text{ mm}^3$  were further analyzed.

(3) Regions of interest (ROIs) analysis. To quantitatively compare the activations in different motor areas, three pairs of ROIs (M1, SMA and PMC), determined by

statistical parametric mapping and anatomical landmarks, were selected for further analysis. The activation volume of each ROI in each subject was calculated. We then performed two sets of paired  $t$ -tests on activation volume. In the first set, we compared each ROI with its corresponding ROI on the opposite side of the brain (i.e. left vs. right side) for both the dominant hand movement and the non-dominant movement tasks. In the second set, we compared the dominant hand movement task with the non-dominant hand task for each ROI. Finally, the time course of the most significantly activated voxel in each ROI was analyzed to examine whether the activation was time-locked to the motor tasks.

## 2 Results

As Fig. 2 shows, the contralateral M1, SMA and PMC were significantly activated during simple finger movements with both dominant and non-dominant hand, whereas the ipsilateral SMA and PMC were only activated during non-dominant hand movements. Activation in

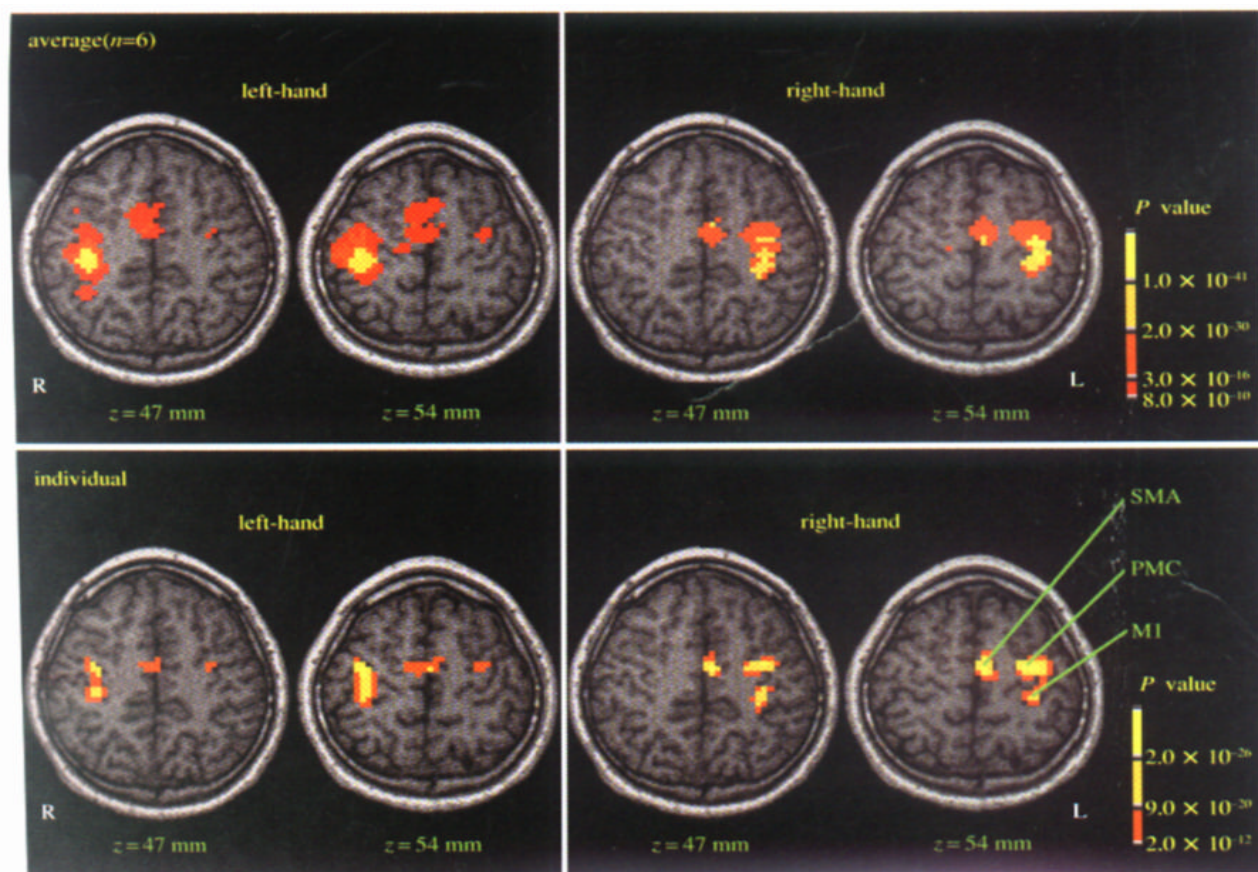


Fig. 2. Statistical parametric maps of brain activation. The upper panel shows the statistical parametric maps of brain activation ( $P < 8.0 \times 10^{-10}$ ,  $n = 6$ ) averaged from six subjects during left and right hand movements, respectively. The lower panel shows statistical parametric maps of brain activation ( $P < 2.0 \times 10^{-12}$ ) from a representative subject during left and right hand movements separately. The color bar encodes the  $P$  values, indicating the statistically significant level. Three major activated motor areas, M1, SMA, and PMC, are noted.  $z$  denotes the superior and inferior level in the Talairach coordinates<sup>[19]</sup>.

these ROIs was further analyzed as follows.

( ) M1. As shown in Fig. 2, contralateral M1 was significantly activated during both the dominant and the non-dominant hand movements, whereas ipsilateral M1 was not reliably activated. Quantitative analysis revealed that activation volume of contralateral M1 was significantly larger than that of ipsilateral M1 for hand movements (Table 1). Moreover, for both sides of M1, activation volume elicited by the contralateral hand movements was significantly larger than that elicited by

the ipsilateral hand movements (right M1:  $t = 4.237, P < 0.01$ ; left M1:  $t = 5.003, P < 0.01$ ). Further analysis of the time course of this ROI indicates that the MR signal in the contralateral M1 was consistently time-locked to task block both during the dominant and during the non-dominant hand movements. Specifically, the signal increased shortly after the onset of the task, kept at a high level during the task, and decreased after the task was over. However, these task-locked changes were not observed in the ipsilateral M1 (Fig. 3).

Table 1 The activation volumes (voxel<sup>3</sup>) ( $M \pm SD$ ) of the three pairs of ROI during left and right hand movements and statistical values (paired  $t$ -test)

	Left hand				Right hand			
	activated volume (right)	activated volume (left)	$t$	$P$	activated volume (right)	activated volume (left)	$t$	$P$
M1	213 ± 135	8 ± 10	3.737	< 0.01	29 ± 43	163 ± 81	-3.826	< 0.01
PMC	113 ± 91	85 ± 79	1.957	> 0.05	32 ± 42	159 ± 115	-3.198	< 0.02
SMA	112 ± 104	100 ± 78	0.459	> 0.05	65 ± 82	131 ± 83	-3.146	< 0.02

a) 1 voxel = 3 mm × 3 mm × 3 mm.

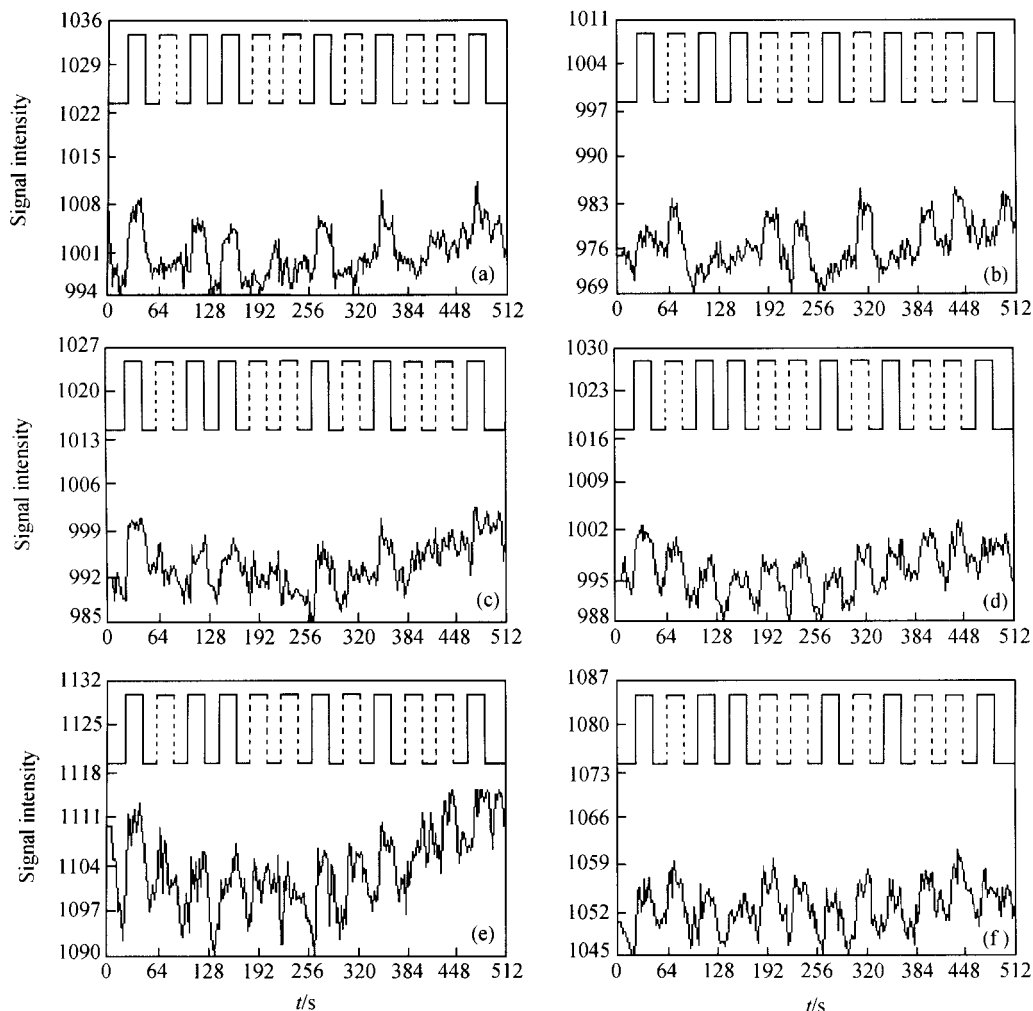


Fig. 3. Mean time course of voxels in ROIs. From top to bottom are the time courses for M1, PMC and SMA. The lines above the time courses indicate the timing of the tasks, the solid line for the left hand task and the dash line for right hand task. (a) Right-M1; (b) left-M1; (c) right-PMC; (d) left-PMC; (e) right-SMA; (f) left-SMA.

( ) PMC. As shown in Fig. 2, dominant hand movements mainly activated contralateral PMC. The activation volume in contralateral PMC was much larger than that in ipsilateral PMC. During the non-dominant hand movements, however, both sides of PMC were significantly activated, although activation volume in ipsilateral PMC was slightly smaller than that in the contralateral PMC. Similarly, as Table 1 shows, activation volume in contralateral PMC was significantly larger than that in the ipsilateral PMC for dominant hand movements, whereas for non-dominant hand movements, although activated volume of the ipsilateral PMC was slightly smaller than that of the contralateral PMC, the difference was not statistically significant. Analysis of the activation volume on each side of PMC during the two hand movements led to a similar conclusion: activation volume of the right PMC (contralateral to non-dominant hand) during the non-dominant hand movements was significantly larger than that during the dominant hand movements ( $t = 2.539$ ,  $P < 0.05$ ), but for the left PMC, difference in activation volume during two movement tasks failed to reach significant level ( $P > 0.05$ ). Fig. 3 shows the mean time course of PMC averaged over all six subjects. The signal change in the right PMC was closely locked to left hand movements, but the signal change in the left PMC was locked to both right and left hand movements.

( ) SMA. As shown in Fig. 2, the dominant hand movements mainly activated contralateral SMA, whereas the non-dominant hand movements activated both sides of SMA, although activation extent of the contralateral SMA was slightly larger than that of the ipsilateral SMA. Similarly, as Table 1 shows, activation volume of contralateral SMA was significantly larger than that of ipsilateral SMA during dominant hand movements, whereas during the non-dominant hand movements. Although activation volume of contralateral SMA was slightly larger than that of ipsilateral SMA, this difference was not statistically significant. A similar conclusion can be drawn through the comparison of activation volume for the two sides of SMA during left and right hand movements. Specifically, for the right SMA, activation volume during the non-dominant hand movements was significantly larger than that during dominant hand movements ( $t = 2.893$ ,  $P < 0.05$ ), whereas the difference in activation volume in the left SMA during the two hand movements failed to reach significance level ( $P > 0.05$ ). However, the averaged time course of SMA indicates (Fig. 3) that modest activation was also observed in the right SMA during the ipsilateral hand movements, and the difference of the MR signal changes between left and right SMA was not as clear as that in PMC.

### 3 Discussion

In the present study, we used fMRI to investigate the activation pattern of motor-related cerebral cortex during

externally-triggered simple voluntary movements. We identified brain areas engaged in movement carried out with the dominant and the non-dominant hand, and analyzed the activation volume and time course of M1, SMA and PMC, to characterize specific roles of the primary cortex and secondary motor areas in such movements. Our data clearly show that simple movements, whether using dominant or non-dominant hand, not only activated contralateral M1 significantly, but also elicited reliable activation in the secondary motor areas (SMA and PMC). This suggests that both the primary motor cortex and secondary motor areas are involved in simple movements. As mentioned in the first part of this paper, whether the secondary motor areas are engaged in simple voluntary movements is a matter of debates. Although some authors provided evidence that the secondary motor areas were activated in some simple movements<sup>[6–8]</sup>, the opponents argue that movement at high rate can increase the complexity of the tasks, which in turn elicited activation in the secondary motor areas<sup>[5]</sup>. However, in the present study, we found that even for very simple movement at low rate (0.5 Hz), reliable activation was still detected in the secondary motor areas. This provides strong evidence for the involvement of the secondary motor areas in simple voluntary movements. One may argue that in this study, the dominant and the non-dominant hand movements were run in the same scan session, in which the subjects must select the hand by the visual cue and this introduced additional demands. However, since we used block design, subjects repeatedly performed the tasks at low rate with the same hand (finger) in each block, and long control periods were inserted between two neighboring blocks. The demands of task would be similar to those under the condition of the dominant and the non-dominant hand movements in two separate scans, both being lower than in the condition in which one needs quick switch between the dominant and the non-dominant hand. Indeed, in their recent PET study, Catalan and his colleagues<sup>[20]</sup> observed significant activation in SMA and contralateral M1 during movements of right finger in one scan. This result indicates that our result is similar to that observed with only one hand finger movement in a scan.

It should be further noted that movement complexity may also be associated with the way of movement initiation, e.g. externally-triggered or self-initiated. As the movement in our task is externally-guided, our data indicate that self-initiation is not necessary for the involvement of secondary motor areas. This conclusion is consistent with the previous studies showing that the secondary motor areas are involved in sensory-guided voluntary movements<sup>[21,22]</sup>. In addition, although the present study observed reliable activation in the secondary motor areas during both dominant and non-dominant hand movements, given there are differences in the agility of the dominant and non-dominant hands, even for the same motor task, the demands for dominant and non-dominant

hand could be different. Accordingly, it is possible that the role of the secondary motor areas during the dominant and the non-dominant hand movements are different. We will examine this point further below.

We compared the activation pattern of the primary motor cortex and secondary motor areas during the dominant and the non-dominant hand movements. We found that contralateral M1 was reliably activated both during the dominant and the non-dominant hand movements, which is quite consistent with previous studies<sup>[9–12]</sup>. However, for the secondary motor areas, particularly for PMC, dominant hand movements mainly activated contralateral side, whereas non-dominant hand movements activated both sides of the secondary motor areas. These results suggest a functional difference between the primary motor cortex and the secondary motor areas. It is reasonable to assume that even for similar movements, the task demand for the non-dominant hand movements should be higher than that for the dominant hand movements owing to the different abilities of the dominant and the non-dominant hand for the reason of heredity and experiences. Therefore, it is very possible that activation in ipsilateral secondary cortex is related to the higher demand during the non-dominant hand movements. Solodkin et al.<sup>[11]</sup> found that for right-handed subjects using right hand, only contralateral motor areas were activated during the simple movements, but bilateral activation was observed during the complex movements. Sadato et al.<sup>[23]</sup> analyzed the correlation of the degree of activation in motor areas with the complexity of motor tasks, and found that activation of M1 was maintained at the same level over different tasks, but activation in the secondary motor areas, particularly on the contralateral side, linearly increased with the complexity of the task. Similarly, in one of their neurophysiological studies, Tanji and Mushiake<sup>[8]</sup> observed that neuronal activity in SMA and PMC was increasing when the complexity and difficulty of the motor task increased, although neuronal activity in M1 did not change over different motor tasks. Taken together, we suggest that contralateral primary motor cortex and secondary motor areas serve as the basic brain structures for voluntary movements, but when more difficult motor tasks or the non-dominant hand movements were performed, ipsilateral secondary motor areas are also recruited. Both Baraldi and his colleagues' study<sup>[24]</sup> and our previous study show that in right-handed subjects both the dominant and the non-dominant hand sequential finger movements, a more complex voluntary movement task, activated bilaterally the secondary motor areas, and the activation volume of left PMC was larger than that of right PMC. These results support our above hypothesis that activation in the ipsilateral secondary motor cortex during the non-dominant hand movement is due to the higher demands of tasks. It has been well established that the secondary motor areas are associated

with preparation and planning of voluntary movements<sup>[7,25–27]</sup>, and neuroanatomical studies suggest that there are reciprocal projections between the left and right SMA and PMC<sup>[28]</sup>. We therefore propose that simple movements with non-dominant hand may be controlled bilaterally by the secondary motor areas through these projections.

As discussed above, even in the same motor task, the task demands for the dominant and the non-dominant hand movements are not identical. Therefore, it is an interesting question whether different activations between the dominant and the non-dominant hand movements are still evident under equal difficulty of task (for instance, after training the non-dominant hand or decreasing the rate of the non-dominant hand movement).

Statistical parametric maps in the present study indicate that activation in SMA and PMC during the dominant and the non-dominant hand movements was very similar, in that only contralateral SMA and PMC were activated during the dominant hand movements, but bilateral activations were found during the non-dominant hand movements. However, closer examination of the time course revealed some differences in activation between PMC and SMA during the dominant and the non-dominant hand movements. Specifically, right PMC only responded to the non-dominant hand movement while right SMA responded to both dominant and non-dominant hand movements. This was not observed in the statistical parametric maps presumably because activation in right SMA during the dominant hand movement was not strong enough to reach the threshold. This indicates that statistical parametric maps should be supplemented with analysis of the time courses to overcome some of its limitations.

In fact, the functional differences between PMC and SMA have been reported in a number of studies. PMC is typically associated with sensory-guided movement preparation and SMA is often associated with self-initiated, internally generated movement preparation and sensory-motion integration<sup>[3,21,22,26,27,29]</sup>. However, most of these studies only aimed at the dominant hand voluntary movement. Further study is needed to investigate the functional differences between the PMC and SMA during the dominant and the non-dominant hand movements.

Finally, it would be interesting to see if the results obtained in the current study can be generalized to left-handed subjects.

**Acknowledgements** This work was supported by the National Natural Science Foundation of China (Grant Nos. 30128005, 30170325 and 30070250), the State Key Basic Research and Development Program (Grant No. G1999054000), and the Technology Fund from the Ministry of Education of China (Grant No. 20010284021).

## References

1. Tanji, J., Sequential organization of multiple movements:

- Involvement of cortical motor areas, *Annu. Rev. Neurosci.*, 2001, 24: 631—651.
2. Andersen, R. A., Snyder, L. H., Bradley, D. C. et al., Multimodal representation of space in the posterior parietal cortex and its use in planning movements, *Annu. Rev. Neurosci.*, 1997, 20: 303—330.
  3. Kollias, S. S., Alkadhi, H., Jaermann, T. et al., Identification of multiple nonprimary motor cortical areas with simple movements, *Brain Res. Rev.*, 2001, 36: 185—195.
  4. Roland, P. E., Larsen, B., Lassen, N. A. et al., Supplementary motor area and other cortical areas in organization of voluntary movements in man, *J. Neurophysiol.*, 1980, 43: 118—136.
  5. Rao, S. M., Binder, J. R., Bandettini, P. A. et al., Functional magnetic resonance imaging of complex human movements, *Neurology*, 1993, 43: 2311—2318.
  6. Colebatch, J. G., Deiber, M. P., Passingham, R. E. et al., Regional cerebral blood flow during voluntary arm and hand movements in human subjects, *J. Neurophysiol.*, 1991, 65: 1392—1401.
  7. Fox, P. T., Fox, J. M., Raichle, M. E. et al., The role of cerebral cortex in the generation of voluntary saccade positron emission tomographic study, *J. Neurophysiol.*, 1985, 54: 348—369.
  8. Tanji, J., Mushiake, H., Comparison of neuronal activity in the supplementary motor area and primary motor cortex, *Cogn. Brain Res.*, 1996, 3: 143—150.
  9. Kim, S. G., Ashe, J., Hendrich, K. et al., Functional magnetic resonance imaging of motor cortex: hemispheric asymmetry and handedness, *Science*, 1993, 261: 615—617.
  10. Volkmann, J., Schnitzler, A., Witte, O. W. et al., Handedness and asymmetry of hand representation in human motor cortex, *J. Neurophysiol.*, 1998, 79: 2149—2154.
  11. Solodkin, A., Hlistik, P., Noll, D. C. et al., Lateralization of motor circuits and handedness during finger movements, *Eur. J. Neurology*, 2001, 8: 425—434.
  12. Dassonville, P., Zhu, X. H., Uurbil, K. et al., Functional activation in motor cortex reflects the direction and the degree of handedness, *Proc. Natl. Acad. Sci. USA*, 1997, 94: 14015—14018.
  13. Liu, C., Weng, X. C., Application of functional magnetic resonance brain imaging in cognitive neuroscience, *Prog. Physiol. Sci.*, 1999, 30: 84—90.
  14. Weng, X. C., Ding, Y. S., Volkow, N. D., Imaging the functioning human brain, *Proc. Natl. Acad. Sci. USA*, 1999, 96: 11073—11074.
  15. Li, X. T., Distribution of right- and left-handed individuals in Chinese population, *Acta Psycholog. Sin.*, 1983, 3: 268—275.
  16. Li, E. Z., Weng, X. C., Han, Y. et al., Asymmetry of brain functional activation: fMRI study under language and music stimulation, *Chin. Med. J.*, 2000, 113: 154—158.
  17. Cui, S. Z., Li, E. Z., Zang, Y. F. et al., Both sides of cerebellum involved in preparation and execution of sequential movements, *NeuroReport*, 2000, 11: 3849—3853.
  18. Cox, R. W., AFNI: Software for analysis and visualization of functional magnetic resonance neuroimaging, *Comput. Biomed. Res.*, 1996, 29: 162—173.
  19. Talairach, J., Tournoux, P., Co-planar Stereotaxic Atlas of the Human Brain, New York: Thieme Medical Publishers, 1988.
  20. Catalan, M. J., Honda, M., Weeks, R. A. et al., The functional neuroanatomy of simple and complex sequential finger movements: a PET study, *Brain*, 1998, 121: 253—264.
  21. Cunnington, R., Windischberger, C., Deecke, L. et al., The preparation and execution of self-initiated and externally-triggered movement: a study of event-related fMRI, *NeuroImage*, 2002, 15: 373—385.
  22. Deiber, M. P., Honda, M., Ibanez, V. et al., Mesial motor areas in self-initiated versus externally triggered movements examined with fMRI: effect of movement type and rate, *J. Neurophysiol.*, 1999, 81: 3065—3077.
  23. Sadato, N., Campbell, G., Ibanez, V. et al., Complexity affects regional cerebral blood flow change during sequential finger movements, *J. Neurosci.*, 1996, 16: 2693—2700.
  24. Baraldi, P., Porro, C. A., Serafini, M. et al., Bilateral representation of sequential finger movements in human cortical areas, *Neurosci. Lett.*, 1999, 269: 95—98.
  25. Weng, X. C., Li, E. Z., Zang, Y. F. et al., Neural correlates of sequential finger movements revealed by event-related fMRI, *NeuroImage*, 2000, 11: S920.
  26. Lee, K. M., Chang, K. H., Roh, J. K., Subregions within the supplementary motor area activated at different stages of movement preparation and execution, *NeuroImage*, 1999, 9: 117—123.
  27. Thickbroom, G. W., Byrnes, M. L., Sacco, P. et al., The role of the supplementary motor area in externally timed movement: the influence of predictability of movement timing, *Brain Res.*, 2000, 874: 233—241.
  28. Wu, J. P., Motor functions of cerebral cortex, in *Principle of Neuroscience* (ed. Han, J. S.), 2nd ed., Beijing: Beijing University of Medicine Press, 1999, 789—804.
  29. Van Oostende, S., Van Hecke, P., Sunaert, S. et al., FMRI studies of the supplementary motor area and the premotor cortex, *NeuroImage*, 1997, 6: 181—190.

(Received October 16, 2002; accepted April 7, 2003)