



Research report

Magnetization transfer imaging reveals the brain deficit in patients with treatment-refractory depression

Ti-Jiang Zhang^{a,b,1}, Qi-Zhu Wu^{a,1}, Xiao-Qi Huang^a, Xue-Li Sun^c, Ke Zou^c, Su Lui^a, Fei Liu^d, Jun-Mei Hu^e, Wei-Hong Kuang^c, Dong-Ming Li^a, Fei Li^a, Hua-Fu Chen^d, Raymond C.K. Chan^f, Andrea Mechelli^g, Qi-Yong Gong^{a,h,*}

^a Huaxi MR Research Center, Department of Radiology, West China Hospital of Sichuan University, Chengdu, PR China

^b Affiliated Hospital of Zunyi Medical College, Guizhou, PR China

^c Department of Psychiatry, West China Hospital of Sichuan University, Chengdu, PR China

^d School of Life Science and Technology, University of Electronic Science and Technology of China, Chengdu, PR China

^e Department of Forensic Psychiatry, School of Primary Medicine and Forensic Medicine, Sichuan University, Chengdu, PR China

^f Neuropsychology and Applied Cognitive Neuroscience Laboratory & Key Laboratory of Mental Health, Institute of Psychology, Chinese Academy of Sciences, Beijing, PR China

^g Section of Neuroimaging, Division of Psychological Medicine, Institute of Psychiatry, King's College London, UK

^h Division of Medical Imaging, Faculty of Medicine, University of Liverpool, UK

ARTICLE INFO

Article history:

Received 25 November 2008

Received in revised form 4 January 2009

Accepted 5 January 2009

Available online 10 February 2009

Keywords:

Treatment resistant/refractory depression

Magnetization transfer imaging

Magnetization transfer ratio

Limbic system

Striatal nucleus

ABSTRACT

Background: Studies on treatment resistant depression (TRD) using advanced magnetic resonance imaging techniques are very limited.

Methods: A group of 15 patients with clinically defined TRD and 15 matched healthy controls underwent magnetization transfer imaging (MTI) and T1-weighted (T1W) imaging. MTI data were processed and analyzed voxel-wised in SPM2. A voxel based morphometric (VBM) analysis was performed using T1W images.

Results: Reduced magnetization transfer ratio was observed in the TRD group relative to normal controls in the anterior cingulate, insula, caudate tail and amygdala-parahippocampal areas. All these regions were identified within the right hemisphere. VBM revealed no morphological abnormalities in the TRD group compared to the control group. Negative correlations were found between MRI and clinical measures in the inferior temporal gyrus.

Limitations: The cross-sectional design and small sample size.

Conclusions: The findings suggest that MTI is capable of identifying subtle brain abnormalities which underlie TRD and in general more sensitive than morphological measures.

© 2009 Elsevier B.V. All rights reserved.

1. Introduction

Despite the progress made over the years in the development of treatments for depressive disorders, treatment refractory depression (TRD) remains a common condition

which accounts for approximately 15–30% of the depressed population and results in significant social costs (Petersen et al., 2001). Recent advances in imaging techniques make it feasible to explore the structural and functional abnormalities associated with TRD; this in turn may lead to a greater understanding of the neuropathology of this condition and facilitate the development of effective treatments (Fagiolini and Kupfer, 2003).

A number of structural MRI studies have been performed on TRD patients and identified structural or anatomical abnormalities in the so-called LCSPT tract (limbic–cortical–

* Corresponding author. Huaxi MR Research Center (HMRR), Department of Radiology, West China Hospital. Guo Xuexiang 37#, Chengdu, 610041, PR China. Tel: +86 28 81812593, fax: +86 28 85423503.

E-mail address: cj.gongqiyong@vip.163.com (Q.-Y. Gong).

¹ Drs. Ti-jiang Zhang and Qi-Zhu Wu contributed to the work equally.

Table 1

Demographic information and disease severity for treatment refractory depression (TRD) and control subjects.

Demographic data	TRD patients (n = 15)	Control subjects (n = 15)
Gender (male/female)	10/5	10/5
Age (years)	33.5 (± 10.2), range 18–51	33.4 (± 10.2), range 18–52
HRSD score	21.1 (± 2.4), range 18–26	
Illness duration (years)	10.3 (± 4.8), range 2–20	

striatal–pallidal–thalamic; Nauta, 1972). Specifically, treatment resistance has been associated with hyperintensity in subcortical gray matter (Steffens et al., 2001) and white matter (Hickie et al., 1995), and with atrophy in the right frontostriatal structures (Shah et al., 2002), the frontal lobe (Coffey et al., 1993) and the temporal lobe (Shah et al., 1998). The hippocampus has also been frequently implicated in TRD (Axelson et al., 1993; Baldwin and Simpson, 1997; Fagiolini and Kupfer, 2003; Mervaala et al., 2000; Simpson et al., 1998). In addition to conventional structural MRI, other MRI techniques, such as the magnetization transfer imaging (MTI), have been applied to the investigation of depressive disorders in recent years (Gunning-Dixon et al., 2008; Kumar et al., 2004; Wyckoff et al., 2003). MTI is sensitive to subtle neuropathological alterations in which the macromolecular concentration changes, thus it also provides complementary disease information to conventional MRI (Filippi and Agosta, 2007; Henkelman et al., 2001).

Currently, there have been very few MTI studies of human depressive disorders. The only three aforementioned studies have all focused on geriatric depression and observed consistently reduced magnetization transfer ratio (MTR) in specific cerebral regions (Gunning-Dixon et al., 2008; Kumar et al., 2004; Wyckoff et al., 2003). To our best knowledge, no MTI study targeting the TRD population has been reported to date. Therefore, in the present study we examined a group of adult patients with TRD using the MTI technique. Our aim was to validate the effectiveness of MTI in characterizing neurobiological abnormalities in TRD. We hypothesized that MTI would be able to detect subtle abnormalities within the LCSPT tract in the brain of patients with TRD relative to matched controls.

2. Materials and methods

2.1. Subjects

Fifteen depressed patients and 15 healthy controls took part in the whole study. Demographic data are presented in Table 1. Depressed subjects were originally recruited for a clinical trial from the Mental Health Center of our university affiliated hospital. Major depression was diagnosed by two qualified psychiatrists using the Structured Clinical Interview according to the DSM-IV criteria (American Psychiatric Association, 1994) and the Research Diagnostic Criteria for major depressive disorder. Exclusion criteria included bipolar disorder, any history of major illness, previous psychiatric therapy before being included in the study, cardiovascular disease, and younger than 18 years or older than 60 years. The severity of depression was assessed using

the 17-item Hamilton Rating Scale for Depression (HRSD; Hamilton, 1967) and to be eligible for the study, only patients who scored 18 or greater were included. All patients were taking antidepressant drugs at the time of the MRI scan and treatment resistance was defined as non-responsiveness to at least two adequate trials (in terms of dosage, duration (6 weeks for each trial), and compliance) of different classes of antidepressants in consistency with previous studies (Furtado et al., 2008; Shah et al., 2002). The non-responsiveness was defined as a less than 50% reduction in HRSD score (Nierenberg and Amsterdam, 1990) after a treatment at a minimum dose of 150 mg/day of imipramine equivalents (dose converted using a conversion table; Lidaka et al., 1997) for 6 weeks. Healthy controls had no history of neuropsychiatric illness or brain injury and were individually matched with the patients for age, sex, handedness and years of education. The study was approved by the local ethical committee, and written informed consent was obtained from all participants.

2.2. MRI acquisition

MR scanning was carried out on a 3.0T MR scanner (EXCITE, GE Signa, Milwaukee, USA). Whole brain MT images were acquired using a 3-dimensional fast low angle shot sequence. One acquisition was performed with, and another without, the magnetization saturation pulse at 1.5 kHz off-resonance, thus generating MT-weighted and non-MT-weighted images separately. Other sequence parameters were: TR/TE = 37/5 ms; flip angle (FA) = 15°; 50 contiguous axial slices with slice thickness = 3 mm; Field of View (FOV) = 24 × 24 cm²; data matrix = 320 × 192. After MTI, high resolution 3-dimensional T1-weighted (T1W) images were acquired employing a spoiled gradient recalled (SPGR) sequence with TR/TE = 8.5/3.4 ms, FA = 12°, 156 axial slices with thickness = 1 mm, axial FOV 24 × 24 cm² and data matrix = 256 × 256.

2.3. Image processing and analysis

MR images from all the subjects were first reviewed to ensure that there were no structural abnormalities or quality flaws. Then data processing and analysis were carried out using the statistical parametric mapping software SPM2, (Wellcome Department of Imaging Neuroscience, London). For each subject, the MT-weighted and non-MT-weighted images were first co-registered using a mutual information registration algorithm. MTR was then calculated on a voxel-by-voxel basis as follows:

$$\text{MTR} = \frac{(M_0 - M_s)}{M_0} \times 100,$$

where M_0 and M_s are the signal intensities without and with the saturation pulse applied. Because the non-MT images are partially T1-weighted, we directly normalized them to the MNI T1W template; and then the transformation parameters were used to normalize the co-registered MTR map. The normalized non-MT images were skull-stripped using the brain extraction tool (BET, <http://www.fmrib.ox.ac.uk/fsl/bet/>), and then used as masks to remove the non-brain tissues on the normalized MTR maps. Finally, MTR maps were smoothed with a Gaussian

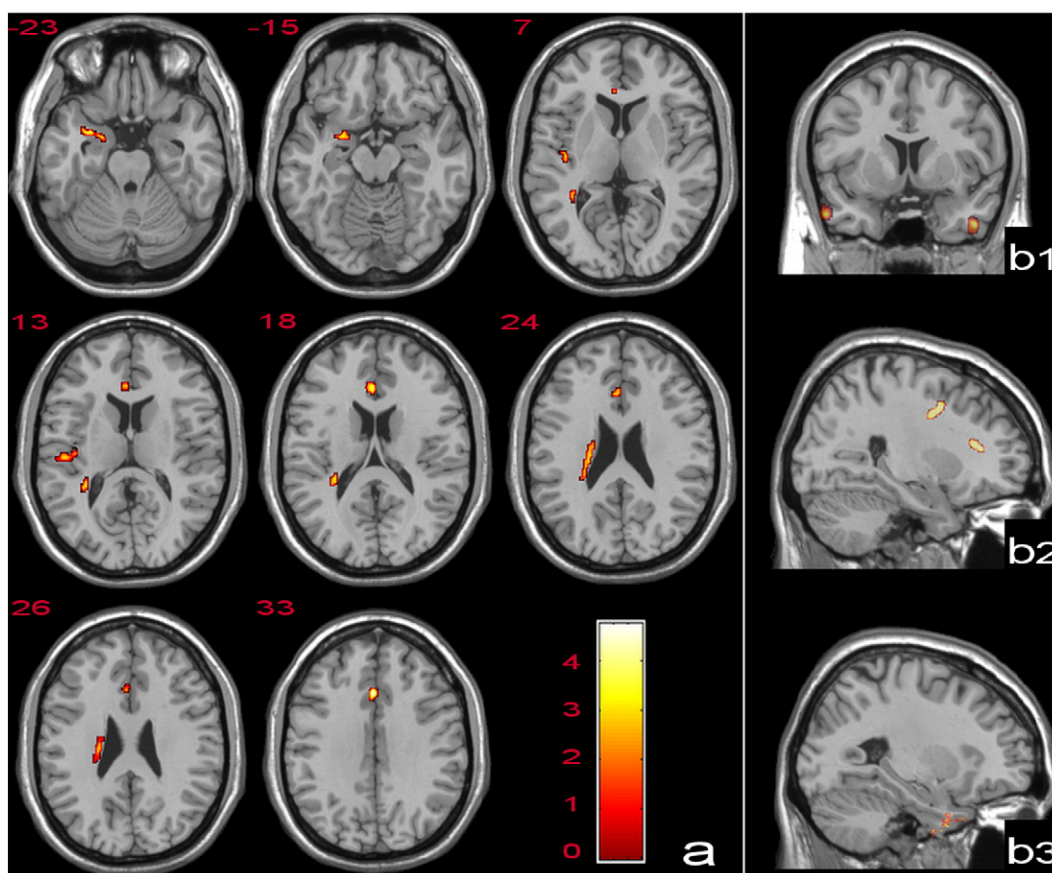


Fig. 1. Panel (a) shows the axial view of the four brain regions with lower MTR in TRD group superimposed on a T1W template. These regions include the ACC, the parahippocampal gyrus and amygdala, the insula and the tail of the caudate nucleus. The color bar signifies the T value of the group analysis. The right panels show significant correlations between MTR and HRSD score (b1), between MTR and duration of illness (b2), and between gray matter volume and HRSD score (b3). All the correlations are negative. The statistical threshold for all correlation analyses was set at cluster level $p < 0.005$, uncorrected; $\kappa > 100$. The superimposed color indicates the strength of the correlation.

kernel of 6-mm full-width half-maximum. After these preprocessing steps, group comparison of MTR maps was performed using the AnCova (analysis of covariates) and the age was used as the nuisance covariate. Then the individual MTR from the AnCova-derived significant clusters were entered into SPSS (SPSS Inc.) for a two-way ANOVA with gender and depression/healthy as two fixed factors. Correlation analysis was made between patients' MTR maps and clinical measures, including the HRSD score and illness duration.

To identify whether subtle morphological abnormalities could be detected in the TRD patients, T1W SPGR images were used to conduct an optimized voxel-based morphometry (VBM) analysis (Good et al., 2001) in SPM2. AnCova was performed to compare group differences in terms of the volumes and concentrations of the gray and white matter with the age and intracranial volume as nuisance covariates, separately. We also performed a voxel-based correlative analysis between gray matter volume (GMV) and HRSD score and illness duration.

3. Results

The TRD group and normal controls were well-matched for gender, age and handedness (Table 1). When we set the

statistical threshold at voxel level $p < 0.01$ (uncorrected) and a cluster extent (κ) of 150 voxels, the group analysis revealed four clusters with reduced MTR (Fig. 1a, Table 2),

Table 2
Clusters present MTR reductions in TRD group compared with healthy controls.

Location (Brodmann area)	Cluster-level		Voxel-level		Talairach coordinates of peak voxels (mm)		
	k_E	$p_{\text{uncorrected}}$	T	$p_{\text{uncorrected}}$			
Cingulate gyrus, (32)	284	0.030	4.74	<0.001	0	23	29
Anterior cingulate, (24)			4.10	<0.001	0	30	16
R anterior cingulate, (25)			2.83	0.004	3	32	3
R parahippocampal gyrus, (34)	215	0.055	4.01	<0.001	21	1	-15
R uncus, (28)			3.94	<0.001	28	3	-20
R insula, (13)	167	0.087	3.49	0.001	43	-12	2
R transverse temporal gyrus, (41)			3.45	0.001	46	-20	13
R caudate tail	296	0.028	3.48	0.001	25	-32	21
R caudate tail			3.44	0.001	30	-39	13
R caudate body			3.29	0.001	19	-18	23

including (1) the anterior cingulate cortex (ACC) and, adjacent, a small part of the corpus callosum; (2) the right amygdala, the right uncus and an adjacent portion of the parahippocampal gyrus; (3) the right posterior insula and connecting transverse temporal gyrus; and (4) the right caudate tail and adjacent subgyral white matter. At voxel level, the significance was not preserved after multiple comparison correction ($p < 0.05$, FWE or FDR). At the cluster level, clusters (1) and (4) reached the significance level of $p < 0.05$, uncorrected, but clusters (2) and (3) did not. In AnCova, when age was allowed to take effect as covariate, only the identified cluster sizes were slightly changed but the coordinates of peak voxels and significance level were not affected. The 2-way ANOVA revealed no significant gender or interaction effects in all four clusters. No marked regional MTR increase in the TRD group compared to the controls was found. Correlative analysis showed that MTR was negatively correlated with HRSD in the bilateral inferior temporal gyrus (Fig. 1b-1), and negatively correlated with illness duration in white matter areas of the left frontal lobe (Fig. 1b-2).

VBM analysis revealed no significant difference between groups no matter with or without the age and intracranial as covariates. A negative correlation between GMV and HRSD score was found in the right medial inferior temporal gyrus (Fig. 1b-3).

4. Discussion

To our knowledge, this is the first MTI study to examine TRD using voxel-based analysis. We found MTR to be lower in the TRD group relative to healthy controls in several right-sided limbic and striatal regions. These results are consistent with our hypothesis that MTI is able to detect subtle abnormalities in the LCSPT tract in TRD brain.

MTI is frequently used in studies of white matter because MTR changes are thought to reflect dys/demyelination or axon loss (Henkelman et al., 2001; Wozniak and Lim, 2006). Recently, however, MTR reductions in gray matter have been consistently reported in MS (Filippi and Agosta, 2007) and a number of psychiatric disorders (Kabani et al., 2002; Kumar et al., 2004). The present study further demonstrates the sensitivity of MTI in revealing gray matter MTR reductions in young and middle-aged TRD patients. Previous MTI investigations into human depressive disorders have focused on geriatric depression (Kumar et al., 2004; Gunning-Dixon et al., 2008; Wyckoff et al., 2003) but our results are not directly comparable due to differences in data analysis.

Using optimized VBM, we did not detect any morphological changes in TRD, although a negative correlation was found between GMV and HRSD score in the right inferior temporal region. In contrast, a recent VBM study found regional gray matter reductions in patients with major depression compared to normal controls (Vasic et al., 2008). This inconsistency may be due to the focus of the present investigation on patients with TRD or the use of a small sample size; the correlation between GMV and HRSD however indicates that VBM could potentially be sensitive to gray matter deficits in the TRD group if larger sample size was employed in future studies. Taken collectively, our findings indicate the sensitivity of MTI in detecting altera-

tions in patients' brain with TRD without apparent morphological abnormalities.

ACC is thought to play an important role in cognitive processing and mood regulation as it is anatomically linked with both dorsal neocortical and ventral paralimbic regions (Mayberg et al., 1997). Consistent with our finding of decreased MTR in the ACC, previous studies of TRD have revealed hypermetabolism using PET (Mayberg et al., 1997) and a change in tissue composition using VBM-MRI (Shah et al., 2002) in this region. The observation of decreased MTR in the amygdala-parahippocampal area is also consistent with previous reports of hippocampal abnormalities (Mervaala et al., 2000; Shah et al., 2002). Negative correlations have also been reported between the chronicity of depressive illness and amygdala-hippocampus volume (Axelson et al., 1993). A SPECT study observed increased cerebral blood flow in the hippocampus-amygdala area in medication-free TRD patients (Hornig et al., 1997). More recently, a study compared female TRD patients to healthy controls and found a volume reduction in the entorhinal cortex which has intimate anatomical and functional connections with the parahippocampal gyrus (Furtado et al., 2008). In contrast, the alterations in the insula and the caudate tail have not been reported by previous studies of TRD, although the insular cortex and caudate have been found to be abnormal in major depression (Drevets, 2000). However, because of the lack of a control group of patients with major depression who were responsive to medication, we were unable to assess whether the observed pattern of abnormalities is specific to TRD or is a common feature of major depression. This limitation of our study should be taken into account when interpreting the results.

Generally, studies of TRD using different imaging modalities have yielded inconsistent results. For example, two independent investigations identified the amygdala-hippocampal area (Hornig et al., 1997) and the rostral ACC (Mayberg et al., 1997) respectively as the unique anatomical site to differentiate TRD patients from depressed patients without TRD. Here we observed MTR reductions in limbic structures and striatal nucleus, which have been reported by some but not all previous studies of TRD. The inconsistency can be explained by different patient recruitment criteria and the use of different imaging methodologies and analytical techniques. Of note is that all the brain regions we identified with reduced MTR are in the right hemisphere, whereas previous TRD studies reported bilateral differences (Kumar et al., 2004; Mayberg et al., 1997; Shah et al., 2002). We speculate that the laterality of our findings may result from limited statistical power due to the small sample size rather than the lateralization of TRD neuropathology.

In summary, although preliminary, the present investigation supports the feasibility and capability of MTI in detecting subtle pathological abnormalities in normal appearing brain tissues in TRD brain, and provides additional evidence for the implication of the LCSPT circuit in TRD. Future studies should adopt a longitudinal design with a larger sample size and a control group of patients with major depression who are responsive to medication, in order to better characterize the neurobiological mechanisms of treatment resistance, and then to help the development of effective therapeutic interventions targeting TRD patients.

Role of funding source

The funders of this work had no role in the data collection, analysis and interpretation and writing the manuscript.

Conflict of interest

No conflict of interest declared.

Acknowledgements

This study was supported by National Natural Science Foundation of China (Grant Nos. 30625024 and 30728017), Programs from the State Education Ministry (Grant Nos. NCET-04-0866; SRFDP-20060610073), National Basic Research Program (Program No: 2007CB512305/2), Key Technology R&D Program (Grant No. 2004BA720A21-01) and National High Technology Program of China (Program No: 2008AA02Z408).

References

- American Psychiatric Association, 1994. Diagnostic and Statistical Manual of Mental Disorders, 4th ed. American Psychiatric Press, Washington, DC.
- Axelson, D.A., Doraiswamy, P.M., McDonald, W.M., Boyko, O.B., Tupler, L.A., Patterson, L.J., Nemeroff, C.B., Ellinwood Jr., E.H., Krishnan, K.R., 1993. Hypercortisolemia and hippocampal changes in depression. *Psychiatry Res.* 47, 163–173.
- Baldwin, R.C., Simpson, S., 1997. Treatment resistant depression in the elderly: a review of its conceptualisation, management and relationship to organic brain disease. *J. Affect. Disord.* 46, 163–173.
- Coffey, C.E., Wilkinson, W.E., Weiner, R.D., Parashos, I.A., Djang, W.T., Webb, M.C., Figiel, G.S., Spritzer, C.E., 1993. Quantitative cerebral anatomy in depression. A controlled magnetic resonance imaging study. *Arch. Gen. Psychiatry* 50, 7–16.
- Drevets, W.C., 2000. Neuroimaging studies of mood disorders. *Biol. Psychiatry* 48, 813–829.
- Fagiolini, A., Kupfer, D.J., 2003. Is treatment-resistant depression a unique subtype of depression? *Biol. Psychiatry* 53, 640–648.
- Filippi, M., Agosta, F., 2007. Magnetization transfer MRI in multiple sclerosis. *J. Neuroimaging* 17 (Suppl 1), 22S–26S.
- Furtado, C.P., Maller, J.J., Fitzgerald, P.B., 2008. A magnetic resonance imaging study of the entorhinal cortex in treatment-resistant depression. *Psychiatry Res.* 163, 133–142.
- Good, C.D., Johnsrude, I.S., Ashburner, J., Henson, R.N., Friston, K.J., Frackowiak, R.S., 2001. A voxel-based morphometric study of ageing in 465 normal adult human brains. *Neuroimage* 14, 21–36.
- Gunning-Dixon, F.M., Hoptman, M.J., Lim, K.O., Murphy, C.F., Klimstra, S., Latoussakis, V., Majcher-Tascio, M., Hrabe, J., Ardekani, B.A., Alexopoulos, G.S., 2008. Macromolecular white matter abnormalities in geriatric depression: a magnetization transfer imaging study. *Am. J. Geriatr. Psychiatry* 16, 255–262.
- Hamilton, M., 1967. Development of a rating scale for primary depressive illness. *Br. J. Soc. Clin. Psychol.* 6, 278–296.
- Henkelman, R.M., Stanisz, G.J., Graham, S.J., 2001. Magnetization transfer in MRI: a review. *NMR Biomed.* 14, 57–64.
- Hickie, I., Scott, E., Mitchell, P., Wilhelm, K., Austin, M.P., Bennett, B., 1995. Subcortical hyperintensities on magnetic resonance imaging: clinical correlates and prognostic significance in patients with severe depression. *Biol. Psychiatry* 37, 151–160.
- Hornig, M., Mozley, P.D., Amsterdam, J.D., 1997. HMPAO SPECT brain imaging in treatment-resistant depression. *Prog. Neuro-psychopharmacol. Biol. Psychiatry* 21, 1097–1114.
- Iidaka, T., Nakajima, T., Suzuki, Y., Okazaki, A., Maehara, T., Shiraishi, H., 1997. Quantitative regional cerebral flow measured by Tc-99m HMPAO SPECT in mood disorder. *Psychiatry Res.* 68, 143–154.
- Kabani, N.J., Sled, J.G., Chertkow, H., 2002. Magnetization transfer ratio in mild cognitive impairment and dementia of Alzheimer's type. *Neuroimage* 15, 604–610.
- Kumar, A., Gupta, R.C., Albert Thomas, M., Alger, J., Wyckoff, N., Hwang, S., 2004. Biophysical changes in normal-appearing white matter and subcortical nuclei in late-life major depression detected using magnetization transfer. *Psychiatry Res.* 130, 131–140.
- Mayberg, H.S., Brannan, S.K., Mahurin, R.K., Jerabek, P.A., Brickman, J.S., Tekell, J.L., Silva, J.A., McGinnis, S., Glass, T.G., Martin, C.C., Fox, P.T., 1997. Cingulate function in depression: a potential predictor of treatment response. *Neuroreport* 8, 1057–1061.
- Mervaala, E., Fohr, J., Kononen, M., Valkonen-Korhonen, M., Vainio, P., Partanen, K., Partanen, J., Tiihonen, J., Viinamaki, H., Karjalainen, A.K., Lehtonen, J., 2000. Quantitative MRI of the hippocampus and amygdala in severe depression. *Psychol. Med.* 30, 117–125.
- Nauta, W.J., 1972. Neural associations of the frontal cortex. *Acta Neurobiol. Exp. (Wars)* 32, 125–140.
- Nierenberg, A.A., Amsterdam, J.D., 1990. Treatment-resistant depression: definition and treatment approaches. *J. Clin. Psychiatry* 51, 39–47 Suppl. discussion 48–50.
- Petersen, T., Gordon, J.A., Kant, A., Fava, M., Rosenbaum, J.F., Nierenberg, A.A., 2001. Treatment resistant depression and axis I co-morbidity. *Psychol. Med.* 31, 1223–1229.
- Shah, P.J., Ebmeier, K.P., Glabus, M.F., Goodwin, G.M., 1998. Cortical grey matter reductions associated with treatment-resistant chronic unipolar depression. Controlled magnetic resonance imaging study. *Br. J. Psychiatry* 172, 527–532.
- Shah, P.J., Glabus, M.F., Goodwin, G.M., Ebmeier, K.P., 2002. Chronic, treatment-resistant depression and right fronto-striatal atrophy. *Br. J. Psychiatry* 180, 434–440.
- Simpson, S., Baldwin, R.C., Jackson, A., Burns, A.S., 1998. Is subcortical disease associated with a poor response to antidepressants? Neurological, neuropsychological and neuroradiological findings in late-life depression. *Psychol. Med.* 28, 1015–1026.
- Steffens, D.C., Conway, C.R., Dombek, C.B., Wagner, H.R., Tupler, L.A., Weiner, R.D., 2001. Severity of subcortical gray matter hyperintensity predicts ECT response in geriatric depression. *J. ECT* 17, 45–49.
- Vasic, N., Walter, H., Hose, A., Wolf, R.C., 2008. Gray matter reduction associated with psychopathology and cognitive dysfunction in unipolar depression: a voxel-based morphometry study. *J. Affect. Disord.* 109, 107–116.
- Wozniak, J.R., Lim, K.O., 2006. Advances in white matter imaging: a review of in vivo magnetic resonance methodologies and their applicability to the study of development and aging. *Neurosci. Biobehav. Rev.* 30, 762–774.
- Wyckoff, N., Kumar, A., Gupta, R.C., Alger, J., Hwang, S., Thomas, M.A., 2003. Magnetization transfer imaging and magnetic resonance spectroscopy of normal-appearing white matter in late-life major depression. *J. Magn. Reson. Imaging* 18, 537–543.