




Contents lists available at ScienceDirect

Progress in Neuro-Psychopharmacology & Biological Psychiatry

journal homepage: www.elsevier.com/locate/pnp

White matter reduction in patients with schizophrenia as revealed by voxel-based morphometry: An activation likelihood estimation meta-analysis

Xin Di ^{a,b}, Raymond C.K. Chan ^{b,c,*}, Qi-yong Gong ^d^a Neuropsychology and Applied Cognitive Neuroscience Laboratory, Department of Psychology, Sun Yat-Sen University, Guangzhou, China^b Neuropsychology and Applied Cognitive Neuroscience Laboratory, Institute of Psychology, Chinese Academy of Sciences, Beijing, China^c Key Laboratory of Mental Health, Institute of Psychology, Chinese Academy of Sciences, Beijing, China^d Huaxi MR Research Centre, Department of Radiology, West China Hospital/West China School of Medicine, Sichuan University, Chengdu, China

ARTICLE INFO

Article history:

Received 7 June 2009

Received in revised form 10 July 2009

Accepted 30 August 2009

Available online 7 September 2009

Keywords:

Activation likelihood estimation

Meta-analysis

Schizophrenia

Voxel-based morphology

White matter

ABSTRACT

Schizophrenia is thought to be a mental disorder caused by the disconnection of brain regions. Cumulative evidence of white matter deficit in patients with schizophrenia has been reported using voxel-based morphometry (VBM), but these studies have not been quantitatively reviewed. In the study reported herein, we used activation likelihood estimation (ALE) analysis to quantitatively estimate focal white matter abnormalities in patients with schizophrenia. Seventeen studies that compared the white matter deficit of patients with schizophrenia and healthy controls were ascertained. The frontal white matter regions and internal capsule revealed consistent white matter reduction in patient groups relative to healthy controls, suggesting a clear focal white matter deficit in patients with schizophrenia. These results support the macro-circuit theory of white matter change in schizophrenia.

© 2009 Elsevier Inc. All rights reserved.

1. Introduction

Schizophrenia has long been considered a disconnection between different cortical areas (Friston and Frith, 1995; Stephan et al., 2006). For example, distinct gray matter networks have been identified to be abnormal in patients with schizophrenia in comparison with healthy controls (Glahn et al., 2008). Given that white matter constitutes the anatomical infrastructure for neural connectivity, it is reasonable to hypothesize the existence of white matter abnormalities in patients with schizophrenia.

Using magnetic resonance imaging (MRI), several studies have shown white matter abnormalities in patients with schizophrenia relative to healthy controls. The whole brain white matter volume was found to be decreased by 1% in schizophrenia patients (Wright et al., 2000). Using region of interest (ROI) analysis, some studies have reported decreases in the white matter volume of the frontal lobes (Buchanan et al., 1998; Hulshoff Pol et al., 2002), but the data on the frontal lobe deficit has not been conclusive. Recently, voxel-based morphometry (VBM) analysis (Ashburner and Friston, 2000) has been

used extensively to estimate focal white matter abnormalities in the whole brain volume (e.g. Sigmundsson et al., 2001; Sowell et al., 2000; Paillère-Martinot et al., 2001). However, most VBM studies have not reported consistent white matter deficits in patients with schizophrenia (Hulshoff Pol et al., 2004). Diffusion tensor imaging (DTI) for evaluating the organization and coherence of white matter fiber tracts has also been used extensively to estimate white matter abnormalities in schizophrenia patients. However, the findings were inconclusive (Kanaan et al., 2005), until subjected to meta-analysis (Ellison-Wright and Bullmore, 2008).

VBM analysis is a statistical method extensively used to compare the structural differences of MRI images between two groups of individuals. It registers individual brain volume on a standard template and voxel-wise statistics are used to find voxels across the whole brain volume where there are significant differences between two groups. This kind of mass-univariate statistics has a problem of multiple comparisons. Although several methods for the correction of such comparisons have been used in VBM studies, clusters of false positives cannot be fully excluded, which could explain the inconsistent findings. In addition, several other limitations of the VBM approach such as poor spatial registration (Bookstein, 2001) and sample selection differences can also lead to inconsistencies. Hence, analysis across studies is needed to estimate consistent white matter abnormalities in patients with schizophrenia.

Activation likelihood estimation (ALE, Turkeltaub et al., 2002) is a relatively new method to compensate for the limitations of VBM. It treats a foci reported by a single study as an activation likelihood, and

Abbreviations: ALE, activation likelihood estimation; DTI, Diffusion tensor imaging; FA, fractional anisotropy; FDR, false discovery rate; FES, first-episode schizophrenia; FWHM, full-width half-maximum; MNI, Montreal Neurological Institute; MRI, magnetic resonance imaging; ROI, region of interest; VBM, voxel-based morphometry; WMC, white matter concentration; WMV, white matter volume.

* Corresponding author. Institute of Psychology, Chinese Academy of Sciences, 4A Datun Road, Beijing 10010, China.

E-mail addresses: rckchan@psych.ac.cn, rckchan2003@yahoo.com.hk (R.C.K. Chan).

estimates consistent activation clusters among different studies. Although several ALE meta-analyses have investigated structural abnormalities in brain gray matter (Ellison-Wright et al., 2008a; Fornito et al., 2009; Glahn et al., 2008) and diffusion tensor abnormalities in white matter (Ellison-Wright and Bullmore, 2008) of patients with schizophrenia, white matter morphometry abnormalities have not been addressed.

In the present study, we systematically reviewed VBM studies of white matter change in patients with schizophrenia. Although these studies varied from patient samples and VBM processing protocols, we used a quantitative ALE meta-analysis to verify whether there is a consistent focal white matter deficit among schizophrenia patients in the published VBM studies.

2. Methods

2.1. Paper selection

We used the key words “voxel based morphometry,” “schizophrenia” and “white matter” to search for appropriate studies in the MEDLINE and PubMed databases. Studies were selected according to the following inclusion criteria: 1) they had to be research articles published in international journals; 2) they had to use VBM analysis to investigate white matter density change in the MRI dataset; 3) they had include a control group and a direct comparison of patients with schizophrenia and healthy controls; and 4) the results had to be normalized to a stereotaxic standardized space such as the Montreal Neurological Institute (MNI) space or the Talairach space (Talairach and Tournoux, 1988), and the coordinates of the activation areas had to be explicitly reported. In addition, we searched the reference lists of the studies identified for potential inclusion.

Table 1 shows that 17 articles met the inclusion criteria for the ALE meta-analysis (twelve studies of chronic schizophrenia, four studies of first-episode schizophrenia (FES), and one study that pooled chronic and FES patients to compare them to healthy controls). A total of 712 patients and 639 healthy controls were included in the meta-analysis. All of the studies reported white matter reduction, but two articles also reported white matter increases. Because two papers were not sufficient for us to run an ALE meta-analysis, we only conducted it for white matter reduction.

2.2. Activation likelihood estimation

The analyses were conducted in the Talairach space, with activation coordinates that were originally reported in MNI space converted using Lancaster's transform (Lancaster et al., 2007). Some of the papers used Brett's formulation to convert from MNI to Talairach (Brett, 1999), so the results were first converted back to MNI coordination, and then transformed into the Talairach space using Lancaster's transform.

The meta-analysis was carried out using GingerALE software (Laird et al., 2005). The idea behind ALE analysis is that the peak coordinates reported in VBM studies should be viewed as probability distributions around themselves (Turkeltaub et al., 2002). In practical terms, an ALE map was constructed based on 65 foci from seventeen studies (see Table 1), and then convolved with a 3D Gaussian kernel. Because the smoothing kernels used in the reviewed VBM studies ranged from 4 mm to 12 mm full-width half-maximum (FWHM) for an average of 9.04 mm, we used a smoothing kernel with 10 mm FWHM to construct the ALE map. Then we simulated activation maps with randomly distributed foci equal to the number of foci in the ALE analysis using a permutation test with 5000 iterations. The clusters identified in the meta-analysis were obtained after controlling the false discovery rate (FDR) at $p < 0.05$ and applying a cluster extent threshold of 100 voxels. Given the activated clusters, we further examined which studies reported foci located in specific clusters. Because four out of the eleven identified clusters were contributed by a single study under $p < 0.05$, a more stringent threshold FDR of $p < 0.01$ was used to present the results. The label of the white matter structure was identified according to the white matter atlas (Wakana et al., 2004).

3. Results

Four clusters were identified in the ALE analysis under FDR $p < 0.01$ and $k > 100$. As illustrated in Fig. 1 and Table 2, several regions, including the frontal white matter regions and the bilateral internal capsule, show consistent white matter deficit in patients with schizophrenia compared to healthy controls.

Two clusters were activated in the frontal white matter regions (peak Talairach coordinates at 20, 46, 26 and $-8, 48, -2$). Four out of the seventeen studies reported white matter reduction in these two

Table 1

Summary of articles included in the meta-analysis (FES, first-episodic schizophrenia; FWHM, full-width half-maximum; WMC = white matter concentration; WMV = white matter volume).

No.	Study	Patients/ male	Mean age of patients	Controls/ male	Duration of illness	Percentage taking antipsychotic medication	Type	Smoothing FWHM (mm)	White matter measure
1	Ananth et al. (2002)	20	10	20	10	15.8	All	12	WMV
2	Antonova et al. (2005)	45	27	43	25	16.9	78%	12	WMV
3	Bassitt et al. (2007)	50	38	30	21	11.4	All	12	WMV
4	Chua et al. (2007)	26	12	38	18	0.33	No	4.4	WMC
5	Hulshoff Pol et al. (2004)	159	112	158	106	12.3	98%	8	WMC
6	Pagsberg et al. (2007)	29	11	29	11	2.1	62%	12	WMV
7	Paillère-Martinot et al. (2001)	20	20	20	20	10	90%	10	WMC
8	Price et al. (2006)	16	12	12	4	<1 month	All	6	WMV
9	Seok et al. (2007)	30	15	22	11	7.5	All	6	WMC
10	Shapleske et al. (2002)	72	72	32	32	11.5	All	2D 4.2	WMC
11	Sigmundsson et al. (2001)	27	26	27	25	13.9	N/A	2D 4.2	WMC
12	Spalletta et al. (2003)	28	14	28	14	11	All	10	WMC
13	Suzuki et al. (2002)	45	23	42	22	5.2	All	12	WMC
14	Whitford et al. (2007)	41	26	47	33	0.69	All	12	WMV
15	Witthaus et al. (2008)	23	16	29	17	N/A	26%	12	WMV
16	Wolf et al. (2008)	28	20	14	9	5.82	96%	8	WMC
17	Zhou et al. (2003)	53	27	48	26	3.88	98%	12	WMC

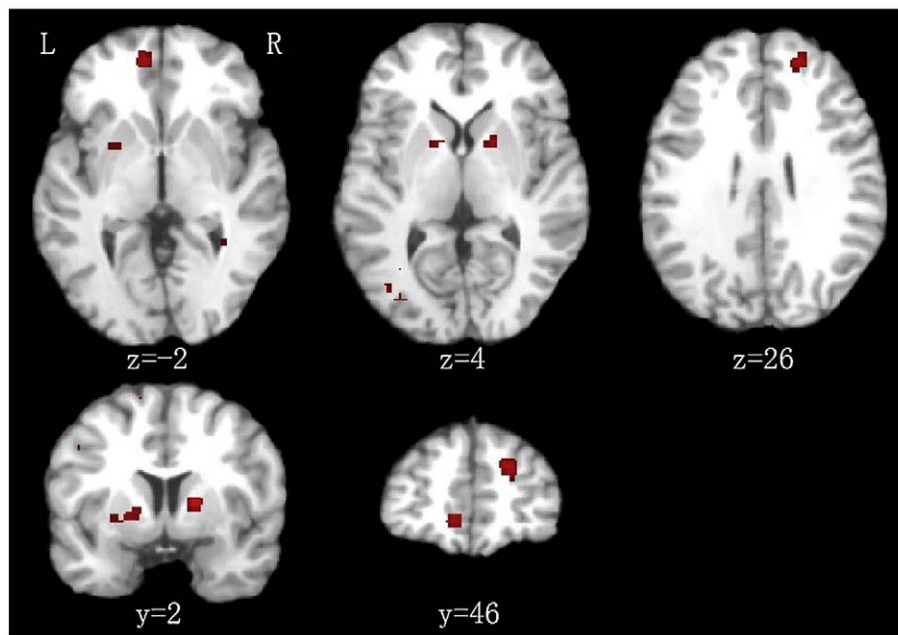


Fig. 1. White matter reduction in patients with schizophrenia compared to healthy controls, displayed on a three-dimensional rendered brain with the anterior part of the left hemisphere removed. Significance threshold with a false discovery rate at $p < 0.01$.

regions (Bassitt et al., 2007; Paillère-Martinot et al., 2001; Spalletta et al., 2003; Witthaus et al., 2008). The remaining two clusters were in the bilateral internal capsule (peak Talairach coordinates at 16, 4, 8 and $-16, 2, 2$). Three out of the seventeen studies reported white matter reduction in these two regions (Chua et al., 2007; Suzuki et al., 2002; Zhou et al., 2003).

4. Discussion

Using the quantitative ALE method, we evaluated the consistent focal white matter deficit of patients with schizophrenia in VBM studies. Multiple white matter fasciculi reductions were found in patients with schizophrenia, including in the frontal white matter regions and the bilateral internal capsule. The current ALE results were consistent with evidence from other techniques. Frontal lobe white matter reductions in patients with schizophrenia have been widely reported in region-of-interest white matter volumetry studies (Breier et al., 1992; Buchsbaum et al., 2006; Hulshoff Pol et al., 2002; Mathalon et al., 2003; Sanfilippo et al., 2000; Wible et al., 2001) and fractional anisotropy (FA) studies using diffusion tensor imaging (Hao et al., 2006; Hoptman et al., 2002; Kitamura et al., 2005; Kumra et al., 2004; Lim et al., 1999; Minami et al., 2003; Steel et al., 2001; Wolkin et al., 2003). Our results demonstrated white matter abnormalities in the right and medial frontal white matter regions, which is in line with these studies. The deficit in the internal capsule was consistent with the findings of many diffusion tensor imaging studies (Buchsbaum et al., 2006; Kubicki et al., 2005, 2007; Szeszko et al., 2005). The white

matter reductions in the frontal white matter and deep temporal white matter regions were also in line with the findings of a recently published ALE analysis of diffusion tensor FA studies (Ellison-Wright and Bullmore, 2008).

Although there is clear evidence to support the disconnection theory in schizophrenia, the evidence for aberrant long-range anatomical connections is still less convincing (Stephan et al., 2006, 2009). The present results, together with an ALE analysis of diffusion tensor FA studies (Ellison-Wright and Bullmore, 2008), provide clear evidence of macro-circuit white matter changes in patients with schizophrenia (Konrad and Winterer, 2008). The macro-circuit theory proposes that specific white matter tracts are disrupted in schizophrenia, rather than the uniform reduction of white matter throughout the brain.

The current results suggest that the VBM approach can be a useful method in estimating white matter abnormalities in schizophrenia. However, there are some technical points we should consider in future studies. First, depending on whether or not modulation was performed, VBM measured either white matter concentration (WMC) or white matter volume (WMV). These measures assessed different aspects of white matter deficit, and may therefore reflect different pathological processes (Fornito et al., 2009). Second, the smoothing kernel could also have affected the VBM results. For example, Honea et al. (2005) illustrated that a smaller smoothing kernel led to the detection of a greater number of regions implicated in schizophrenia. As shown in Tables 1 and 2, the activated clusters in the present study were contributed by studies using both WMC measure and WMV

Table 2

Activation likelihood estimation results of white matter reduction in patients with schizophrenia.

Cluster #	Volume (mm ³)	Peak ALE value	Talairach coordinates			Label	# of studies contributed to the cluster
			x	y	z		
1	544	0.010283	20	46	26	R. frontal white matter	3, 7, 15
2	352	0.011932	16	4	8	R. internal capsule	4, 17
3	336	0.010507	-8	48	-2	L. frontal white matter	12, 15
4	248	0.008271	-16	2	2	L. internal capsule	13, 17

The peak coordinates were in Talairach system. (L. left; R. right).

measure, and studies using both larger kernel (10–12 mm) and small kernel (4–8 mm). There was no evidence for an influence of WMC/WMV measure or smoothing kernel on WM changes. Given the limited number of studies in the present meta-analysis, further study using a larger sample size should be conducted to clarify these issues.

However, the present results revealed only a small number of studies contributing to the positive results, which is in contrast to another DTI meta-analysis (Ellison-Wright and Bullmore, 2008). This may suggest that the regional white matter reduction in schizophrenia could not be measured robustly by VBM technique. The reason may be that the real effect of white matter deficit is shape change, which cannot be measured properly by univariate measurement. It will be appropriate to use multivariate statistics for VBM analysis (e.g. Kawasaki et al., 2007), and the FA or tractography technique for DTI data (Kanaan et al., 2006; Kubicki et al., 2007; Kyriakopoulos et al., 2008; Nestor et al., 2008) in the future to describe white matter abnormalities more accurately.

Each significant cluster in the present results was only contributed by 2–3 studies. This suggests that the current ALE algorithm has high sensitivity but low robustness. One possible shortcoming of the conventional ALE analysis is that it uses a fixed effect analysis estimating consistency across individual foci rather than individual studies. This may be problematic in some condition (Eickhoff et al., 2009), and cannot weight studies by factors such as sample size. Some algorithm considering random effect analysis should be considered in the future, such as Genome Scan Meta-Analysis (Ellison-Wright et al., 2008b), and random effect ALE analysis (Eickhoff et al., 2009).

A number of factors can affect brain structure changes in schizophrenia, such as the stage of illness (Glahn et al., 2008), antipsychotic use, and age effects (Jones et al., 2006). The heterogeneity of the reviewed studies could thus have led us to underestimate the results of white matter reduction. These factors should be further explored in a study using a larger sample size.

In conclusion, we identified consistent white matter reduction in schizophrenia patients in the frontal white matter regions and the bilateral internal capsule. These findings, taken in conjunction with a meta-analysis of diffusion tensor studies (Ellison-Wright and Bullmore, 2008), provide evidence for macro-circuit white matter changes in schizophrenia.

Acknowledgements

This study was partially supported by the Project-Oriented Hundred Talents Programme (07CX031003) of the Institute of Psychology, the Knowledge Innovation Project of the Chinese Academy of Sciences (KSCX2-YW-R-131), a grant from the National Natural Science Foundation of China (30770723), and two grants from the National Basic Research Programme (973 Programme No. 2007CB512302 and 2007CB512305). These funding agents had no further role in the study design, the collection, analysis and interpretation of the data, the writing of the manuscript or the decision to submit this paper for publication.

References

- Ananth H, Popescu I, Critchley HD, Good CD, Frackowiak RSJ, Dolan RJ. Cortical and subcortical gray matter abnormalities in schizophrenia determined through structural magnetic resonance imaging with optimized volumetric voxel-based morphometry. *Am J Psychiatry* 2002;159(9):1497–505.
- Antonova E, Kumari V, Morris R, Halari R, Anilkumar A, Mehrotra R, et al. The relationship of structural alterations to cognitive deficits in schizophrenia: a voxel-based morphometry study. *Biol Psychiatry* 2005;58(6):457–67.
- Ashburner J, Friston KJ. Voxel-based morphometry—the methods. *NeuroImage* 2000;11(6):805–21.
- Bassitt D, Neto M, Castro C, Busatto G. Insight and regional brain volumes in schizophrenia. *Eur Arch Psychiatry Clin Neurosci* 2007;257(1):58–62.
- Bookstein FL. “Voxel-based morphometry” should not be used with imperfectly registered images. *Neuroimage* 2001;14(6):1454–62.
- Breier A, Buchanan RW, Elkashef A, Munson RC, Kirkpatrick B, Gellad F. Brain morphology and schizophrenia: a magnetic resonance imaging study of limbic, prefrontal cortex, and caudate structures. *Arch Gen Psychiatry* 1992;49(12):921–6.
- Brett M. The MNI brain and the Talairach atlas. Cambridge: Imagers; 1999. <http://www.mrc-cbu.cam.ac.uk/Imaging/mnispace.html>.
- Buchanan RW, Vldar K, Barta PE, Pearlson GD. A structural evaluation of the prefrontal cortex in schizophrenia. *Am J Psychiatry* 1998;155(8):1049–55.
- Buchsbaum MS, Friedman J, Buchsbaum BR, Chu KW, Hazlett EA, Newmark R, et al. Diffusion tensor imaging in schizophrenia. *Biol Psychiatry* 2006;60(11):1181–7.
- Chua SE, Cheung C, Cheung V, Tsang JT, Chen EY, Wong JC, et al. Cerebral grey, white matter and CSF in never-medicated, first-episode schizophrenia. *Schizophr Res* 2007;89(1–3):12–21.
- Eickhoff SB, Laird AR, Grefkes C, Wang LE, Zilles K, Fox PT. Coordinate-based activation likelihood estimation meta-analysis of neuroimaging data: a random-effects approach based on empirical estimates of spatial uncertainty. *Hum Brain Mapp* 2009. doi:10.1002/hbm.20718.
- Ellison-Wright I, Bullmore E. Meta-analysis of diffusion tensor imaging studies in schizophrenia. *Schizophr Res* 2008. doi:10.1016/j.schres.2008.11.021.
- Ellison-Wright I, Glahn D, Laird AR, Thelen S, Bullmore E. The anatomy of first-episode and chronic schizophrenia: an anatomical likelihood estimation meta-analysis. *Am J Psychiatry* 2008a;165(8):1015–23.
- Ellison-Wright I, Ellison-Wright Z, Bullmore E. Structural brain change in attention deficit hyperactivity disorder identified by meta-analysis. *BMC Psychiatry* 2008b;8:51.
- Fornito A, Yücel M, Patti J, Wood SJ, Pantelis C. Mapping grey matter reductions in schizophrenia: an anatomical likelihood estimation analysis of voxel-based morphometry studies. *Schizophr Res* 2009. doi:10.1016/j.schres.2008.12.011.
- Friston KJ, Frith CD. Schizophrenia: a disconnection syndrome? *Clin Neurosci* 1995;3(2):89–97.
- Glahn DC, Laird AR, Ellison-Wright I, Thelen SM, Robinson JL, Lancaster JL, et al. Meta-analysis of gray matter anomalies in schizophrenia: application of anatomical likelihood estimation and network analysis. *Biol Psychiatry* 2008;64(9):774–81.
- Hao Y, Liu Z, Jiang T, Gong G, Liu H, Tan L. White matter integrity of the whole brain is disrupted in first-episode schizophrenia. *Neuroreport* 2006;17(1):23–6.
- Honea R, Crow TJ, Passingham D, Mackay CE. Regional deficits in brain volume in schizophrenia: a meta-analysis of voxel-based morphometry studies. *Am J Psychiatry* 2005;162(12):2233–45.
- Hoptman MJ, Volavka J, Johnson G, Weiss E, Bilder RM, Lim KO. Frontal white matter micro-structure, aggression, and impulsivity in men with schizophrenia: a preliminary study. *Biol Psychiatry* 2002;52(1):9–14.
- Hulshoff Pol HE, Schnack HG, Bertens MG, van Haren NE, van der Tweel I, Staal WG, et al. Volume changes in gray matter in patients with schizophrenia. *Am J Psychiatry* 2002;159(2):244–50.
- Hulshoff Pol HE, Schnack HG, Mandl RCW, Cahn W, Louis Collins D, Evans AC, et al. Focal white matter density changes in schizophrenia: reduced inter-hemispheric connectivity. *NeuroImage* 2004;21(1):27–35.
- Jones DK, Catani M, Pierpaoli C, Reeves SJ, Shergill SS, O’Sullivan M, et al. Age effects on diffusion tensor magnetic resonance imaging tractography measures of frontal cortex connections in schizophrenia. *Hum Brain Mapp* 2006;27(3):230–8.
- Kanaan RA, Kim J, Kaufmann WE, Pearlson GD, Barker GJ, McGuire PK. Diffusion tensor imaging in schizophrenia. *Biol Psychiatry* 2005;58(12):921–9.
- Kanaan RA, Shergill SS, Barker GJ, Catani M, Ng VW, Howard R, et al. Tract-specific anisotropy measurements in diffusion tensor imaging. *Psychiatry Res: Neuroimaging* 2006;146(1):73–82.
- Kawasaki Y, Suzuki M, Kherif F, Takahashi T, Zhou S, Nakamura K, et al. Multivariate voxel-based morphometry successfully differentiates schizophrenia patients from healthy controls. *NeuroImage* 2007;34(1):235–42.
- Kitamura H, Matsuzawa H, Shioiri T, Someya T, Kwee IL, Nakada T. Diffusion tensor analysis in chronic schizophrenia: a preliminary study on a high-field (3.0T) system. *Eur Arch Psychiatry Clin Neurosci* 2005;255(3):313–8.
- Konrad A, Winterer G. Disturbed structural connectivity in schizophrenia primary factor in pathology or epiphenomenon? *Schizophr Bull* 2008;34(1):72–92.
- Kubicki M, Park H, Westin CF, Nestor PG, Mulkern RV, Maier SE, et al. DTI and MTR abnormalities in schizophrenia: analysis of white matter integrity. *Neuroimage* 2005;26(4):1109–18.
- Kubicki M, McCarley R, Westin CF, Park HJ, Maier S, Kikinis R, et al. A review of diffusion tensor imaging studies in schizophrenia. *J Psychiatr Res* 2007;41(1–2):15–30.
- Kumra S, Ashtari M, McMeniman M, Vogel J, Augustin R, Becker DE, et al. Reduced frontal white matter integrity in early onset schizophrenia: a preliminary study. *Biol Psychiatry* 2004;55(12):1138–45.
- Kyriakopoulos M, Bargiotas T, Barker GJ, Frangou S. Diffusion tensor imaging in schizophrenia. *Eur Psychiatry* 2008;23(4):255–73.
- Laird AR, Fox M, Price CJ, Glahn DC, Uecker AM, Lancaster JL, et al. ALE meta-analysis: controlling the false discovery rate and performing statistical contrasts. *Hum Brain Mapp* 2005;25(1):155–64.
- Lancaster JL, Tordesillas-Gutiérrez D, Martínez M, Salinas F, Evans A, Zilles K, et al. Bias between MNI and Talairach coordinates analyzed using the ICBM-152 brain template. *Hum Brain Mapp* 2007;28(11):1194–205.
- Lim KO, Hedehus M, Moseley M, de Crespigny A, Sullivan EV, Pfefferbaum A. Compromised white matter integrity in schizophrenia inferred from diffusion tensor imaging. *Arch Gen Psychiatry* 1999;56(4):367–74.
- Mathalon DH, Pfefferbaum A, Lim KO, Rosenbloom MJ, Sullivan EV. Compounded brain volume deficits in schizophrenia-alcoholism morbidity. *Arch Gen Psychiatry* 2003;60(3):245–52.
- Minami T, Nobuhara K, Okugawa G, Takase K, Yoshida T, Sawada S, et al. Diffusion tensor magnetic resonance imaging or disruption of regional white matter in schizophrenia. *Neuropsychobiology* 2003;47(3):141–5.

- Nestor PG, Kubicki M, Niznikiewicz M, Gurrera RJ, McCarley RW, Shenton ME. Neuropsychological disturbance in schizophrenia: a diffusion tensor imaging study. *Neuropsychology* 2008;22(2):246–54.
- Pagsberg AK, Baaré WF, Raabjerg Christensen AM, Fagerlund B, Hansen MB, Labianca J, et al. Structural brain abnormalities in early onset first-episode psychosis. *J Neural Transm* 2007;114(4):489–98.
- Pailière-Martinot ML, Caclin A, Artiges E, Poline JB, Joliot M, Mallet L, et al. Cerebral gray and white matter reductions and clinical correlates in patients with early onset schizophrenia. *Schizophr Res* 2001;50(1–2):19–26.
- Price G, Cercignani M, Bagary MS, Barnes TR, Barker GJ, Joyce EM, et al. A volumetric MRI and magnetization transfer imaging follow-up study of patients with first-episode schizophrenia. *Schizophr Res* 2006;87(1–3):100–8.
- Sanfilippo M, Lafargue T, Rusinek H, Arena L, Loneragan C, Lautin A, et al. Volumetric measure of the frontal and temporal lobe regions in schizophrenia: relationship to negative symptoms. *Arch Gen Psychiatry* 2000;57(5):471–80.
- Seok J, Park H, Chun J, Lee S, Cho H, Kwon JS, et al. White matter abnormalities associated with auditory hallucinations in schizophrenia: a combined study of voxel-based analyses of diffusion tensor imaging and structural magnetic resonance imaging. *Psychiatry Res: Neuroimaging* 2007;156(2):93–104.
- Shapleske J, Rossell SL, Chitnis XA, Suckling J, Simmons A, Bullmore ET, et al. A computational morphometric MRI study of schizophrenia: effects of hallucinations. *Cereb Cortex* 2002;12(12):1331–41.
- Sigmundsson T, Suckling J, Maier M, Williams SCR, Bullmore ET, Greenwood KE, et al. Structural abnormalities in frontal, temporal, and limbic regions and interconnecting white matter tracts in schizophrenic patients with prominent negative symptoms. *Am J Psychiatry* 2001;158(2):234–43.
- Sowell ER, Levitt J, Thompson PM, Holmes CJ, Blanton RE, Kornsand ES, et al. Brain abnormalities in early onset schizophrenia spectrum disorder observed with statistical parametric mapping of structural magnetic resonance images. *Am J Psychiatry* 2000;157(9):1475–84.
- Spalletta G, Tomaiuolo F, Marino V, Bonaviri G, Trequatrini A, Caltagirone C. Chronic schizophrenia as a brain misconnection syndrome: a white matter voxel-based morphometry study. *Schizophr Res* 2003;64(1):15–23.
- Steel RM, Bastin ME, McConnell S, Marshall I, Cunningham-Owens DG, Lawrie SM, et al. Diffusion tensor imaging (DTI) and proton magnetic resonance spectroscopy (MRS) in schizophrenic subjects and normal controls. *Psychiatry Res* 2001;106(3):161–70.
- Stephan KE, Baldeweg T, Friston KJ. Synaptic plasticity and dysconnection in schizophrenia. *Biol Psychiatry* 2006;59(10):929–39.
- Stephan KE, Friston KJ, Frith CD. Dysconnection in schizophrenia: from abnormal synaptic plasticity to failures of self-monitoring. *Schizophr Bull* 2009. doi:10.1093/schbul/sbn176.
- Suzuki M, Nohara S, Hagino H, Kurokawa K, Yotsutsuji T, Kawasaki Y, et al. Regional changes in brain gray and white matter in patients with schizophrenia demonstrated with voxel-based analysis of MRI. *Schizophr Res* 2002;55(1–2):41–54.
- Szeszko PR, Ardekani BA, Ashtari M, Kumra S, Robinson DG, Sevy S, et al. White matter abnormalities in first-episode schizophrenia or schizoaffective disorder: a diffusion tensor imaging study. *Am J Psychiatry* 2005;162(3):602–5.
- Talairach J, Tournoux P. Co-planar stereotaxic atlas of the human brain: 3-dimensional proportional system—an approach to cerebral imaging. New York: Thieme Medical Publishers; 1988.
- Turkeltaub PE, Eden GF, Jones KM, Zeffiro TA. Meta-analysis of the functional neuroanatomy of single-word reading: method and validation. *NeuroImage* 2002;16(3):765–80.
- Wakana S, Jiang H, Nagae-Poetscher LM, van Zijl PCM, Mori M. Fiber tract-based atlas of human white matter anatomy. *Radiology* 2004;230(1):77–87.
- Whitford TJ, Grieve SM, Farrow TF, Gomes L, Brennan J, Harris AW, et al. Volumetric white matter abnormalities in first-episode schizophrenia: a longitudinal, tensor-based morphometry study. *Am J Psychiatry* 2007;164(7):1082–9.
- Wible CG, Anderson J, Shenton ME, Kricun A, Hirayasu Y, Tanaka S, et al, McCarley RW. Prefrontal cortex, negative symptoms, and schizophrenia: an MRI study. *Psychiatry Res* 2001;108(2):65–78.
- Witthaus H, Brüne M, Kaufmann C, Böhner G, Özgürdal S, Gudłowski Y, et al. White matter abnormalities in subjects at ultra high-risk for schizophrenia and first-episode schizophrenic patients. *Schizophr Res* 2008;102(1–3):141–9.
- Wolf RC, Hose A, Frasch K, Walter H, Vasic N. Volumetric abnormalities associated with cognitive deficits in patients with schizophrenia. *Eur Psychiatry* 2008;23(8):541–8.
- Wolkin A, Choi SJ, Szilagy S, Sanfilippo M, Rotrosen JP, Lim KO. Inferior frontal white matter anisotropy and negative symptoms of schizophrenia: a diffusion tensor imaging study. *Am J Psychiatry* 2003;160(3):572–4.
- Wright IC, Rabe-Hesketh S, Woodruff PWR, David AS, Murray RM, Bullmore ET. Meta-analysis of regional brain volumes in schizophrenia. *Am J Psychiatry* 2000;157(1):16–25.
- Zhou SY, Suzuki M, Hagino H, Takahashi T, Kawasaki Y, Nohara S, et al. Decreased volume and increased asymmetry of the anterior limb of the internal capsule in patients with schizophrenia. *Biol Psychiatry* 2003;54(4):427–36.